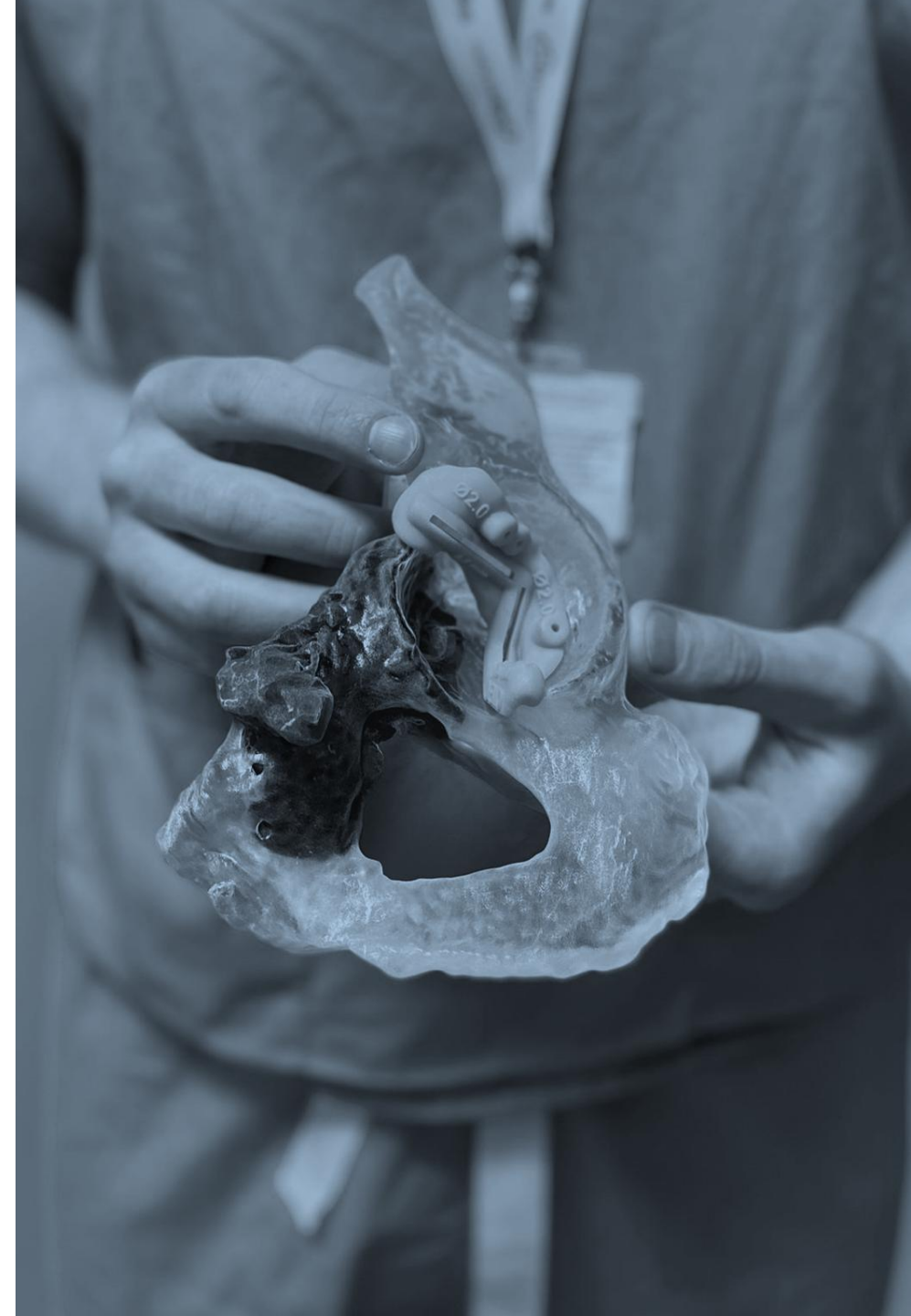



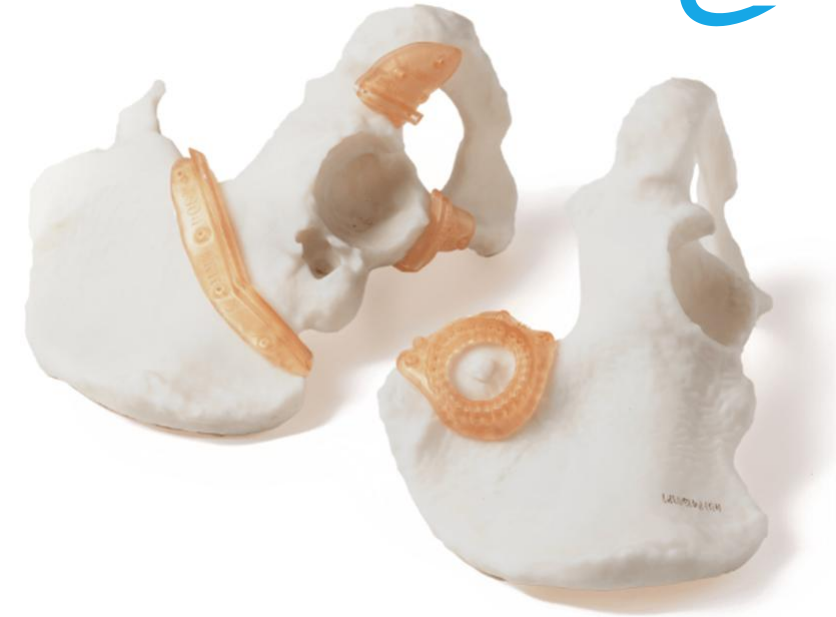Pelvic Orthopedic Oncology

Case Examples

Medical Devices provided in Days, not Weeks



Rapid provision of **FDA approved Personalized Virtual Surgical Planning, Surgical Guides and Models, Designed and Delivered** within a **Week** *



Manufactured in our **Texas Medical Center Cleanroom** facility.

"The fact that Insight can design and rapidly make guides within in a week is a big deal...and also get through surgery without extensive blood loss or other complications"

Dr Herrick Siegel

Specialist, Adult Reconstruction and Orthopedic
Oncology. University of Alabama Birmingham Medicine

SPECIALITIES (ADULT & PEDIATRIC)

- **Upper limb**
- **Lower limb**
- **Pelvis**
- **VSP with Partner Implants**
- **Surgical Guides**
- **Allograft guides**

<https://www.insightsurgery.com/oncology-solutions/>

CASE STUDY:

Sacral & Iliac Tumor Resection

SUMMARY

This patient presented with an aggressive tumor invading both the ilium and sacrum where the growth had begun to compromise a number of sacral roots.

The surgeon planned to resect the tumor with safe margins while attempting to preserve as much bone and neurovascular structures as possible, for optimum recovery and function post-operation.

DESCRIPTION

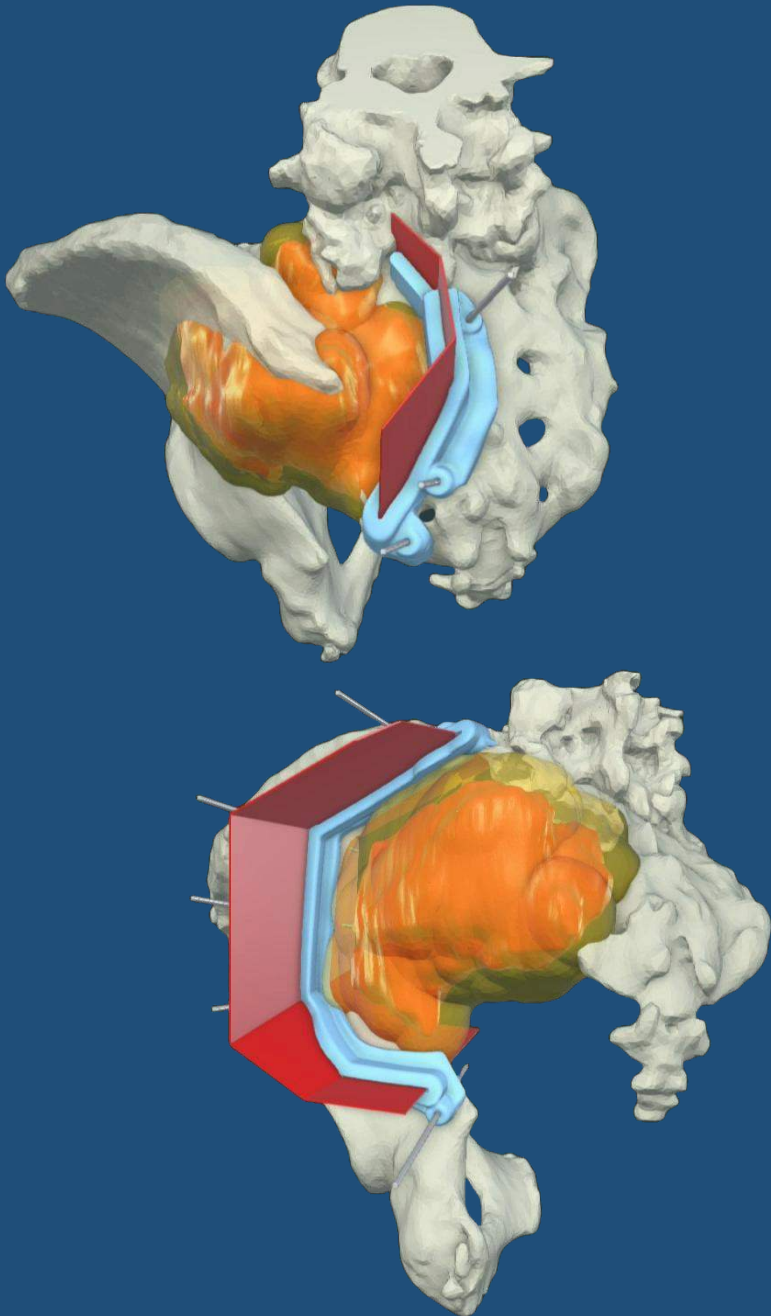
Following the creation of a 3D anatomical model from the CT and MRI scans, three guides were proposed. Two for the sacrum - one anterior guide and one posterior guide. This allowed for maximum bone and nerve conservation whilst also ensuring adequate margins. These two guides would join up distally to allow for the complete resection of the affected region of the sacrum.

The third guide allowed for resection of the tumor affecting the hemipelvis and used wider margins to those used for the sacrum..

OUTCOME / BENEFITS

Due to soft tissue obstruction the guides were used to define the initial location and angles of the cutting planes, after which the surgeon completed the cuts freehand.

Negative margins were successfully achieved, and intra-operative efficiency was enhanced for both surgeon and patient.



CASE STUDY:

Giant Cell Tumor Guided Resection

SUMMARY

This patient presented with a giant cell tumor of the right ischium in need of resection. Due to the tumor's close proximity to the acetabulum, care would be needed in margin and osteotomy planning, in order to preserve as much bone as possible.

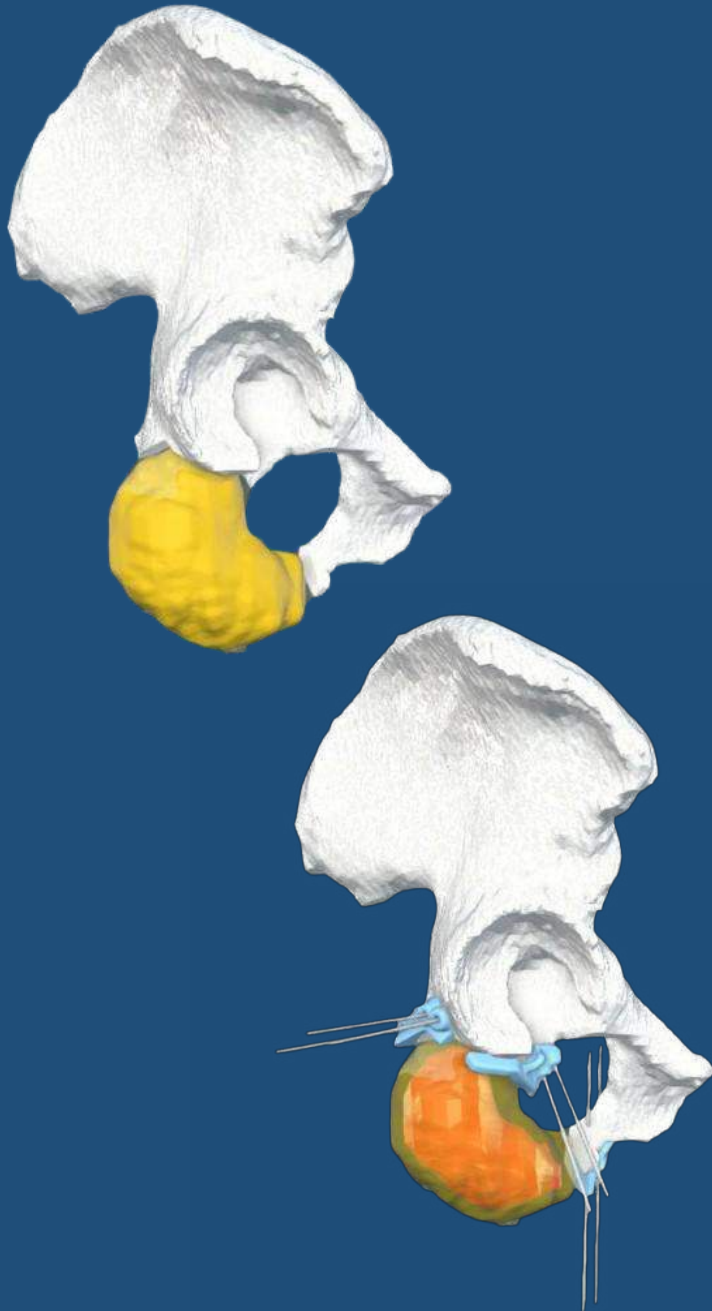
DESCRIPTION

The patient's anatomy was segmented and 3D modelled from the combination of CT and MRI scans. The surgeon then worked with Insight Surgery in calculating their desired margins for bone preservation. With the whole region hard to access, the surgeon would use a high lithotomy approach for increased surgical access to be able to use guides

Three guides were designed in total. One to resect the tumor along the inferior pubic ramus. The anterosuperior and the posterosuperior ischial guides resected around the acetabulum in order to preserve joint anatomy and function. Design emphasized small guide footprints and open flanges due to limited surgical access and the smaller margins.

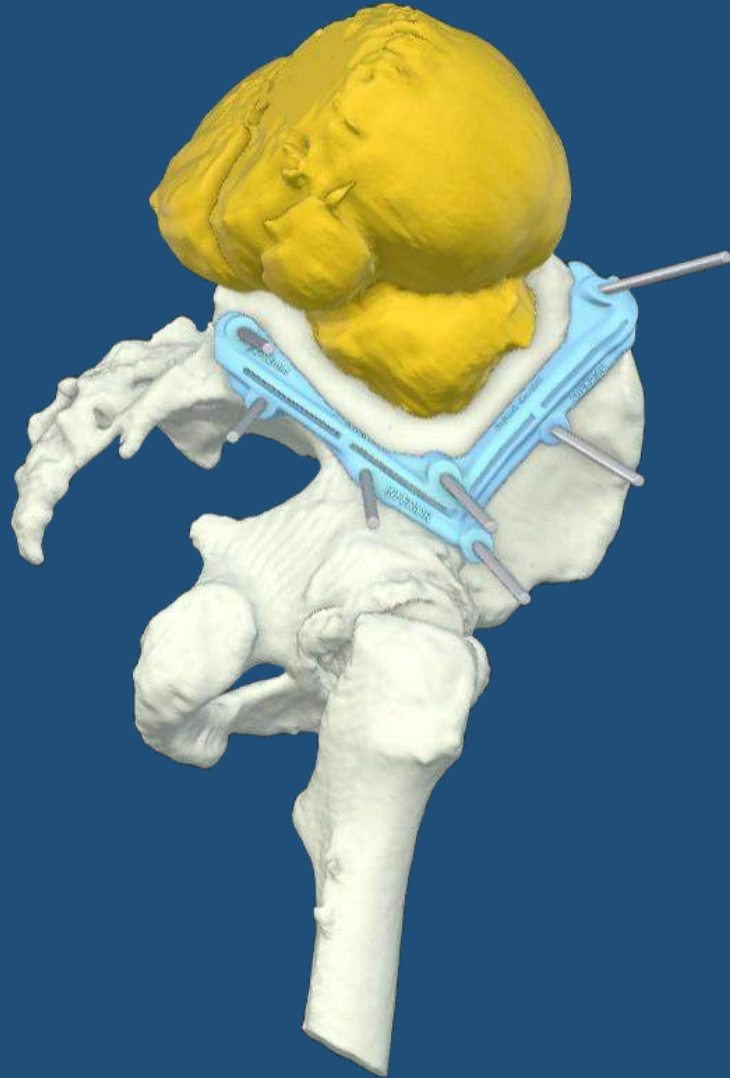
OUTCOME / BENEFITS

The surgery went well, with the guides proving useful for the surgeon given how close the tumor was to the acetabulum, with the anterosuperior guide being of particular importance in marking the cutting for that area of bone.



CASE STUDY:

Pelvic Squamous Cell Carcinoma Resection



SUMMARY

This patient had already undergone both chemotherapy and radiotherapy to treat the squamous cell carcinoma developing in their iliac wing.

However, the mass continued to enlarge, and resection was proposed by the surgeon.

DESCRIPTION

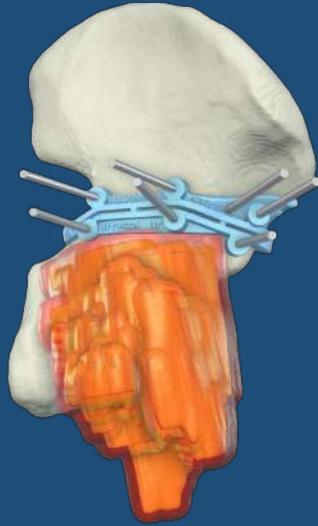
CT and MRI scans were used to construct the virtual 3D model of the patient's pelvis. The tumor was grown with a 10mm allowance to allow for negative margins.

Discussions with the surgeon to plan the cuts resulted in the design of one 'mega' guide which would allow for complete resection. With consideration, Insight Surgery also designed and provided an alternative for the surgeon in the form of two individual guides which would allow the same resection in two stages if placement complications occurred. These two guides shared common K-wire placements for uniform fit.

OUTCOME / BENEFITS

The surgery *"was successful and negative margins were achieved."*

The surgeon appreciated the provision of guide options.

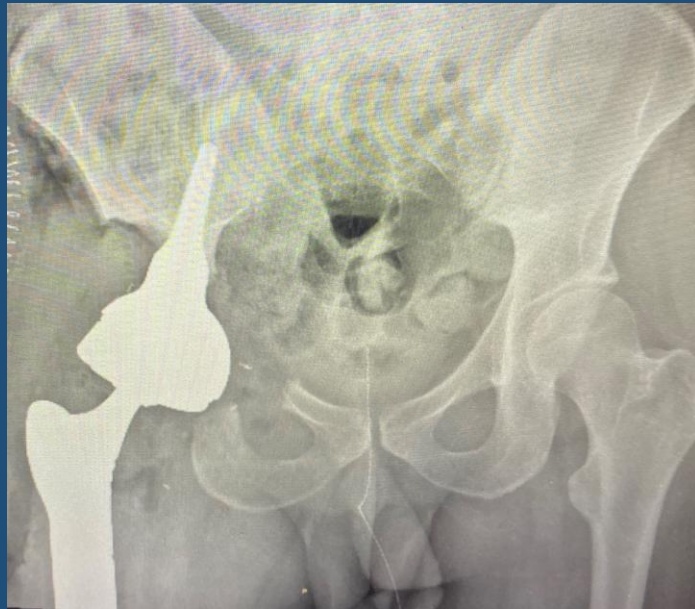


CASE STUDY:

Acetabular Osteosarcoma

SUMMARY

In this exemplar case, the patient presented with an osteosarcoma that had invaded the acetabulum. Insight Surgery provided personalized surgical guides to safely resect the compromised bone whilst maximising bone conservation.



Postoperative X-Ray

DESCRIPTION

Within 5 days of receiving the surgeon's instruction, Insight Surgery was able to rapidly design and manufacture multiple medical devices; patient-specific anatomical models for pre-surgical planning and surgical guides for optimizing the resections.

OUTCOME / BENEFITS

The surgeon commented:

"The patient had an unfortunate and significant progression of disease despite chemotherapy that necessitated a change of surgical plans with a tight window. With the expert help and a true collaborative effort from the teams at Insight and ImplantCast, we were able to implement a precise and patient-specific plan for the patient that made our surgery more efficient and optimized the outcome for the patient. I am thankful for the support and the efficiency with which this was delivered."

CASE STUDY:

Osteosarcoma Resection & Hemipelvectomy

SUMMARY

This patient's osteosarcoma was fast growing and the surgeon had particular concerns about the growth compromising important anatomical structures at and around the sciatic notch, including the sciatic nerve.

A hemipelvectomy was planned to entirely remove the affected part of the hemipelvis, whilst safely preserving as much as bone as possible to allow for subsequent reconstruction with an implant.

DESCRIPTION

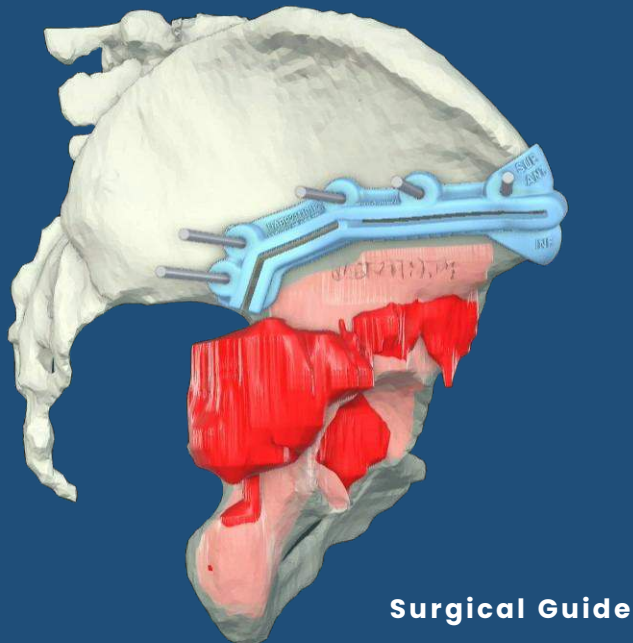
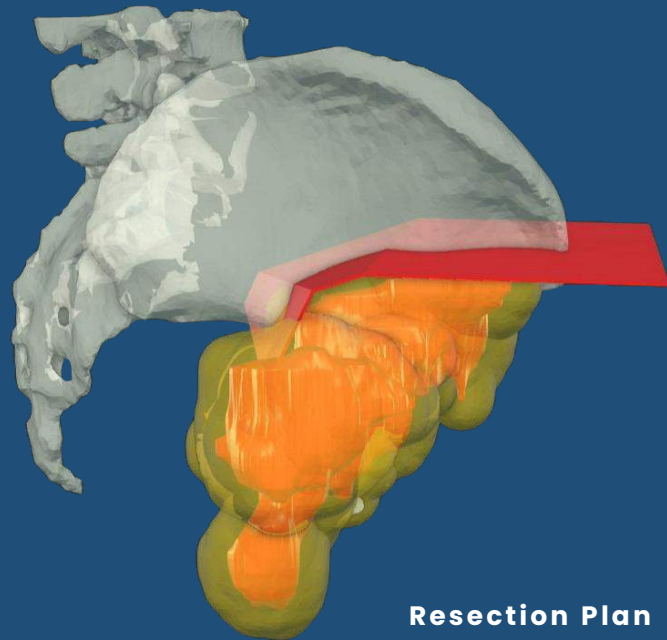
A 3D model was built through a combination of CT and MRI. Two different tumor margins, wider anteriorly and narrower posteriorly, were agreed upon with the surgeon and used to set the resection plane locations and angles. Using the narrower margin posteriorly helped the surgeon to avoid critical neurovascular structures at the sciatic notch and preserve as much bone as possible for reconstruction.

Notably, this case demonstrated Insight Surgery's capability for extremely quick turnaround. Owing to the urgency of the growth, it took less than five days from receiving the scans to delivery of the guides for sterilization prior to use in theater.

OUTCOME / BENEFITS

Virtual planning and intra-operative surgical guide use resulted in a successful hemipelvectomy procedure in 90 minutes. This meant less time in theater for both patient and surgeons compared to a procedure without.

Negative margins were achieved and this resection formed the basis on which the surgeon would reconstruct the joint with a custom implant.



FASTER RECOVERY

Less time in ICU, faster rehabilitation. On average patients stayed 3 less days overall and 1.5 days less in ICU.

FEWER POSITIVE MARGINS

In our study with the UK NHS over 26 real world cases, 13 of the cases that did not use guides had 3 positive margins as opposed to 0 positive margins where guides were used.

INCREASED SURGICAL LISTS

Significant time savings in surgery by using digital planning and guides means more procedures can be added to future surgical lists.

FEWER MAJOR ISSUES

By the use of surgical guides in complex orthopedic oncology cases, an ~18% reduction in major complications during and after was observed.

REDUCED THEATER TIME

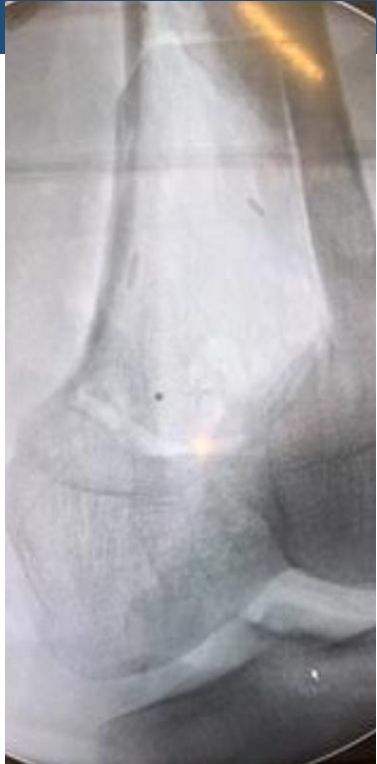Overall, between a 10% to 30% reduction in theater time was observed brought about by the use of digital planning and surgical guides.

REDUCED BLOOD LOSS

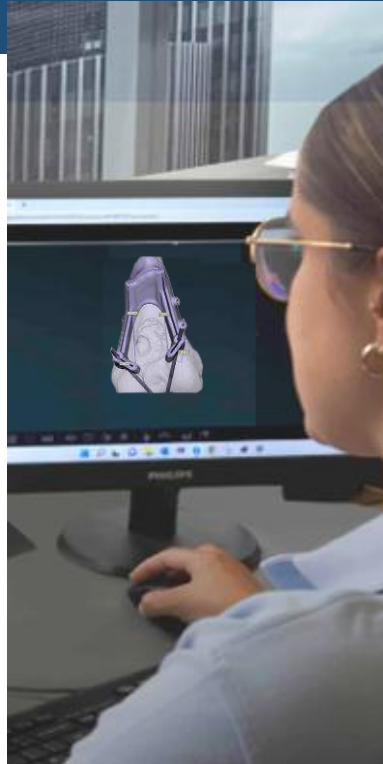
In our studies with the NHS, an overall decrease of ~13% in blood loss was seen which improved the patient outcomes and lowered operational theater costs.

Benefits of Personalized Surgical Solutions

Workflow for Guided Orthopedic Oncology Resection



Patient scan & surgeon case instructions received



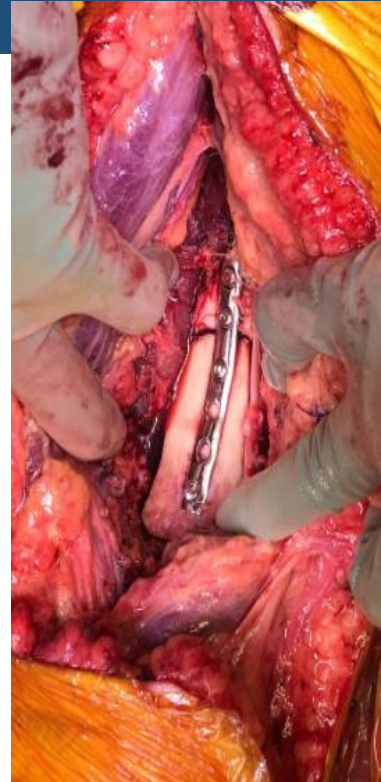Virtual Surgical Plan (VSP) defined with 3D model and Surgical Guide



Final review & approval of VSP and devices by surgeon



3D printing of medical devices in our in-house cleanrooms



Surgery is performed



Digital Planning. Personalized Solutions

Medical Devices provided in Days, not Weeks