



insight surgery
Digital Planning & Personalized Solutions

3D SOLUTIONS FOR PEDIATRIC CARDIOLOGY BROCHURE

3D PRINTED ANATOMICAL MODELS,
VIRTUAL MODELLING, TRAINING
SIMULATORS

SUMMARY / INDEX

WITHIN THE FOLLOWING AREAS

- Congenital cardiology
- Pediatric cardiac surgery
- Pediatric cardiology education and training

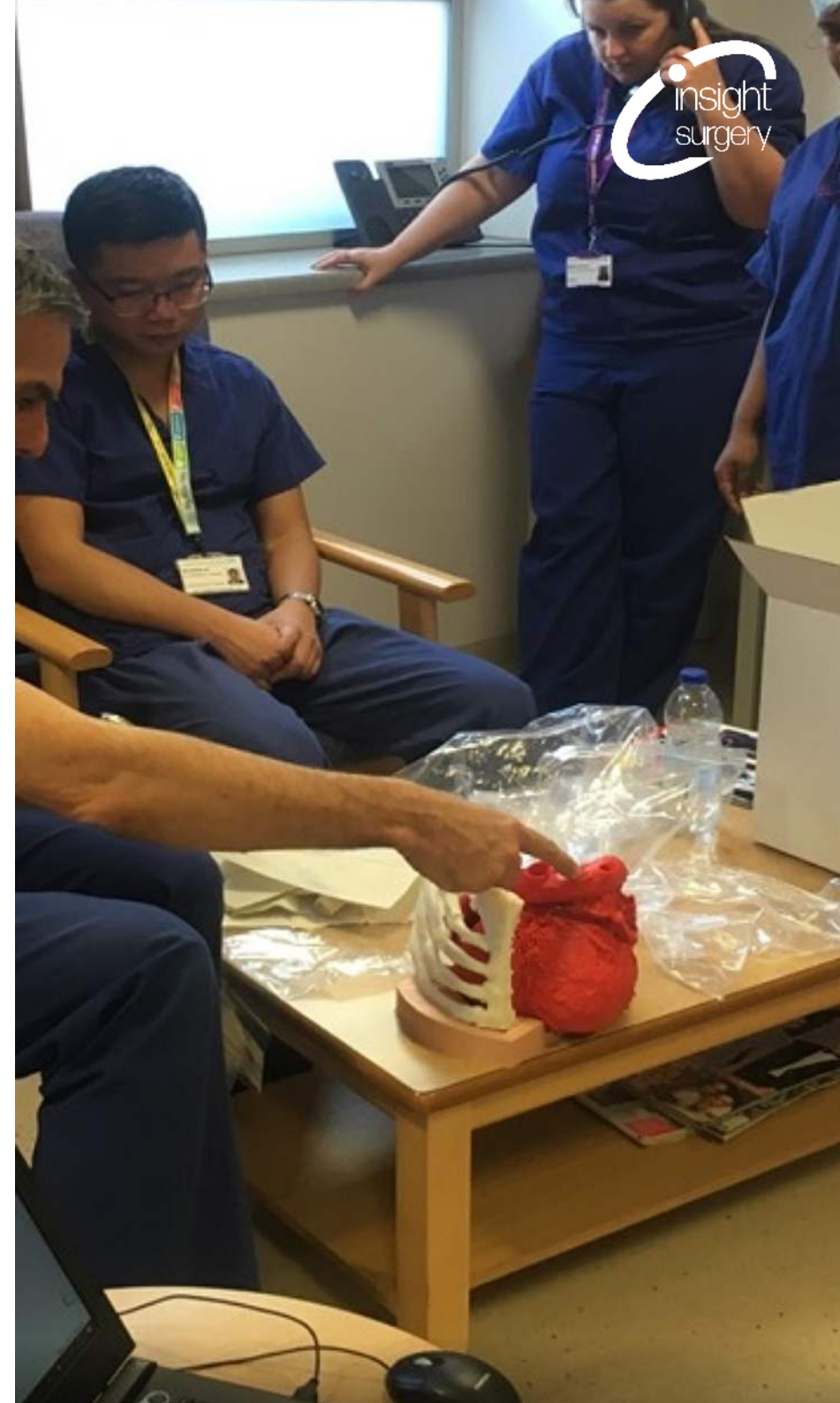SUMMARY OF CARDIOLOGY PRODUCTS & SOLUTIONS

3D PRINTED PATIENT-SPECIFIC ANATOMICAL MODELS

1. Pre-surgical assessment, planning and simulation
2. Intra-surgical use
3. Patient communication
4. Intra-operative reference
5. Post-operative review
6. Colleague education and training

3D PRINTED SIMULATORS

1. Basic surgical skills
2. Advanced pathology simulators



Case Summary

A cardiac surgeon at a children's hospital was presented with a pediatric patient in potential need of an interventricular repair, as a result of a ventricular septal defect.

A patient-specific anatomical model was requested to help the surgeon and his colleagues determine the best course of treatment for the patient's condition.

Description

Insight Surgery segmented the patient's data and created a virtual model of the heart. This was then 3D printed in transparent material at the request of the surgeon and labelled to assist interpretation.

The surgeon presented the model at the multi-disciplinary team meeting where it was analysed alongside other patient imaging as part of the assessment.

INSIGHT SURGERY CASE STUDY

PEDIATRIC CARDIOLOGICAL PRE-SURGICAL PLANNING

SPECIALITY CARDIOLOGY

PROCEDURE INTERVENTRICULAR REPAIR OF SEPTUM

DEVICE 3D PRINTED PATIENT-SPECIFIC ANATOMICAL MODEL



OUTCOME / BENEFITS

The combination of the 3D model with conventional imaging resulted in a more informed decision to proceed with the interventricular repair. Using the model in the pre-surgical planning made for a safer live procedure and the operation was carried out without complication for the patient.

The model was also added to the departments growing collection of 3D printed models, to be used in future teaching and training of aortic rerouting procedures at the hospital.

CASE SUMMARY

A surgeon and his team at a children's hospital were required to treat a patient in need of an Aorto-Left Ventricular Tunnel (ALVT) repair. ALVT, an extremely rare congenital defect involving an extracardiac channel connecting the ascending aorta, above the sino-tubular junction, to the left or right ventricular cavity. Without surgical intervention, heart failure is very likely.

A patient-specific anatomical model was requested to assist the team's pre-surgical planning and communication.

DESCRIPTION

Insight Surgery segmented the MRI scan of the patient's heart structure before using it to calculate the blood volume flowing through it.

The model was then 3D printed in a white and rigid material for the surgical team, enabling them to fully visualise the condition of the patient's heart, and formulate the best plan of approach for the upcoming repair.

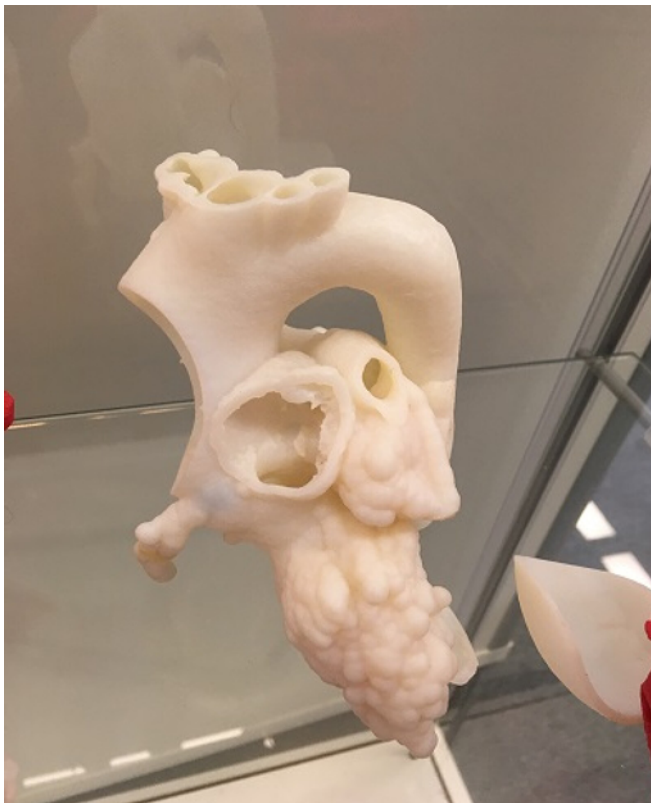INSIGHT SURGERY CASE STUDY

PEDIATRIC CARDIOLOGICAL PRE-SURGICAL PLANNING

SPECIALITY: CARDIOLOGY

PROCEDURE: AORTO-LEFT VENTRICULAR TUNNEL REPAIR

DEVICE: 3D PRINTED PATIENT-SPECIFIC ANATOMICAL MODEL



OUTCOME / BENEFITS

This patient-specific model allowed the surgical team to plan the procedure for a condition which has an incidence rate as low as 0.001% of all congenital heart diseases. The planning time itself was also reduced.

The model was described as being of great use in explaining this rare congenital condition to nurses, cardiologists, and to the patient's family. 3D printing in this case provided a superior method of communication than 2D scans alone.

Case Summary

The cardiology team at a children's hospital needed to treat a very young patient with a ventricular septal defect (VSD), patent ductus arteriosus (PDA) and pulmonary atresia (PA).

The treatment plan would involve the placement of a stent into the ductal area to maintain communication between the pulmonary artery. A model was requested to assist in pre-surgical planning and simulation of this important procedure.

Description

Insight Surgery segmented the patient's scan data and provided a hollow heart model to accurately capture both the internal and external patient-specific morphology of the heart. The model was printed in soft material to mimic the tissue of the heart.

The surgeon was then able to use the model to realistically simulate the insertion of the stent prior to theatre.

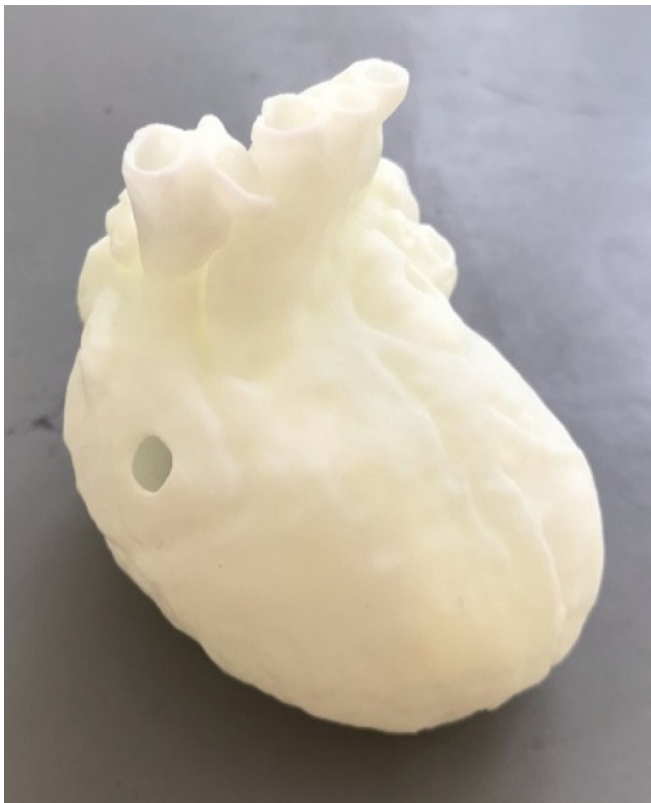
INSIGHT SURGERY CASE STUDY

PEDIATRIC CARDIOLOGICAL PRE-SURGICAL PLANNING AND SIMULATION

SPECIALITY CARDIOLOGY

PROCEDURE SURGERY FOR PULMONARY ATRESIA, VSD AND PATENT DUCTUS ARTERIOSUS

DEVICE 3D PRINTED PATIENT-SPECIFIC ANATOMICAL MODEL



OUTCOME / BENEFITS

Simulation with the anatomically accurate model meant the surgeon could practice their approach and insertion of the stent through the vessels with precision and confidence.

The surgery was successful and was carried out without any complications incurred and the patient is recovering well.

CASE SUMMARY

A pediatric patient presenting with multiple ventricular septal defects (VSD) meant a surgeon and the cardiology department at a children's hospital would need to perform multiple surgeries to correct this congenital heart defect.

A unique model of the patient's anatomy was requested to support the team's surgical planning ahead of live theatre.

DESCRIPTION

Insight Surgery segmented the patient's data and produced a model based on the volume of blood within the heart's chambers rather than the heart itself. It was 3D printed in rigid white material for clear visualisation and handling by the whole team.

The model marked a significant innovative step as Insight Surgery moved beyond providing a copy of the heart to create something highly specific to this type of operation, proving to be of even greater use to the surgeon.

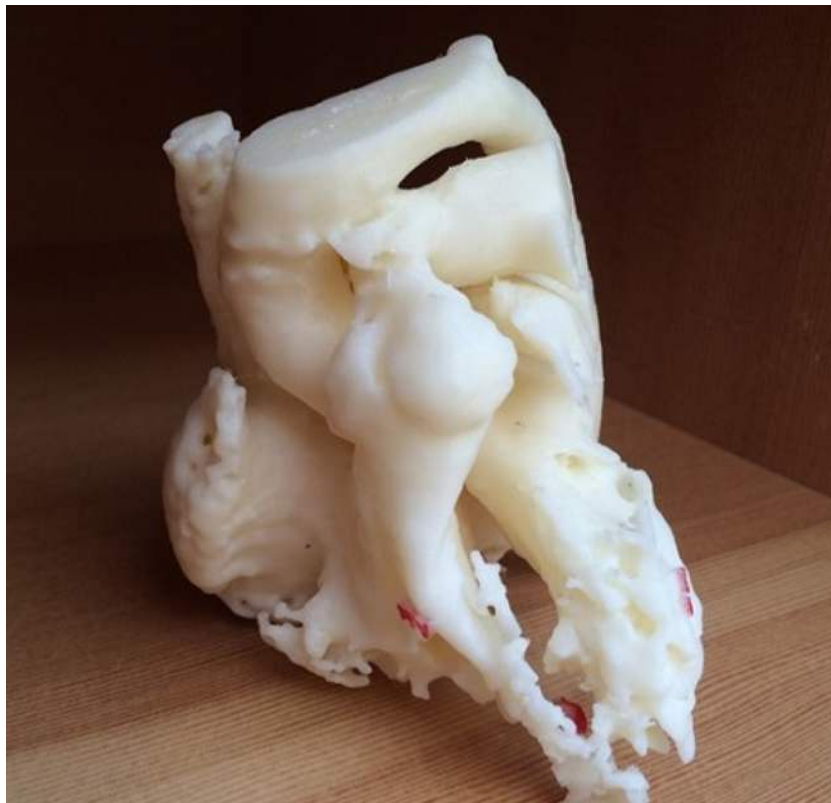INSIGHT SURGERY CASE STUDY

PEDIATRIC CARDIOLOGICAL PRE-SURGICAL PLANNING

SPECIALITY: CARDIOLOGY

PROCEDURE: MULTIPLE VENTRICULAR SEPTAL DEFECT PATCHING

DEVICE: 3D PRINTED PATIENT-SPECIFIC ANATOMICAL MODEL



OUTCOME / BENEFITS

The volume modelling application of 3D printing is an extremely useful technique to indirectly image malformations of the heart by printing the blood volume within structural cavities. The surgeon said *"this is a very impressive and imaginative way to use 3D printing for organ imaging. In this case, we were able to complement the visualisation of the cardiac defects and make the decision that it might be possible to perform a less invasive procedure"*.

The team decided no further patching of the perforations was necessary and these decisions resulted in a second surgery that was shorter, less complex and held lower risk.

CASE SUMMARY

A pediatric patient at a children's hospital was in need of urgent surgery to close a ventricular septal defect (VSD). The cardiac surgeon required a more thorough visualisation of the patient's heart structure prior to surgery, to help ensure a more successful outcome.

A patient-specific anatomical model was requested by the surgical team to aid in determining the location, shape and size of the ventricular septal defect.

DESCRIPTION

Insight Surgery segmented the patient's CT scan to develop the 3D rendering of the heart. It was then 3D printed in transparent, soft material. The model was sectioned into three parts to provide the team with internal insight into the defect.

In this case the model was delivered within 24 hours of the request due to the urgency of this procedure.

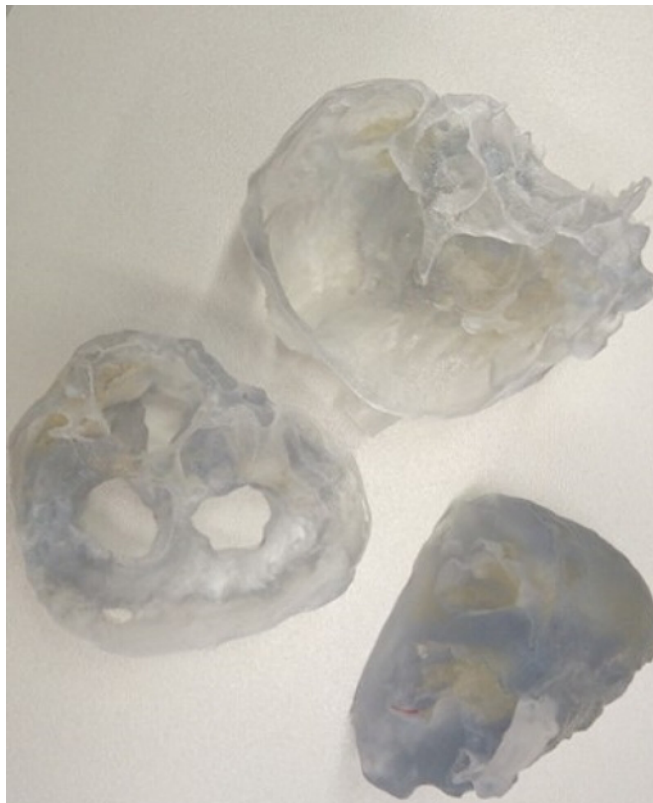
INSIGHT SURGERY CASE STUDY

PEDIATRIC CARDIOLOGICAL PRE-SURGICAL PLANNING

SPECIALITY: CARDIOLOGY

PROCEDURE: VENTRICULAR SEPTAL DEFECT REPAIR

DEVICE: 3D PRINTED PATIENT-SPECIFIC ANATOMICAL MODEL



OUTCOME / BENEFITS

Pre-determining the exact nature of the VSD in the planning phase resulted in a more confident surgical approach to this complex case.

The model will also be used as part of the department's future training of cardiologists and cardiac surgeons who may need to treat patients with similar congenital heart conditions such as VSDs.

CASE SUMMARY

In this case, a surgeon at a children's hospital requested a patient-specific anatomical model in retrospect, as a way to capture and demonstrate an extremely rare pathology of the heart.

The patient presented with Truncus Arteriosus, a congenital condition which occurs when the blood vessel coming out of the heart fails to separate completely and leaves a connection between the aorta and pulmonary artery. Their condition was also complicated by the failure of the aorta to form completely, resulting in an Interrupted Aortic Arch (IAA).

DESCRIPTION

Insight Surgery segmented the patient's data and developed a virtual model of their heart. This was then 3D printed in dual colour, to clearly define the flow of oxygenated (red) and deoxygenated (blue) blood.

Following surgery, the surgeon used the model to help educate surgeons who may encounter a similar condition in the future. It was also used to aid discussions with the patient's parents regarding future treatment.

INSIGHT SURGERY CASE STUDY

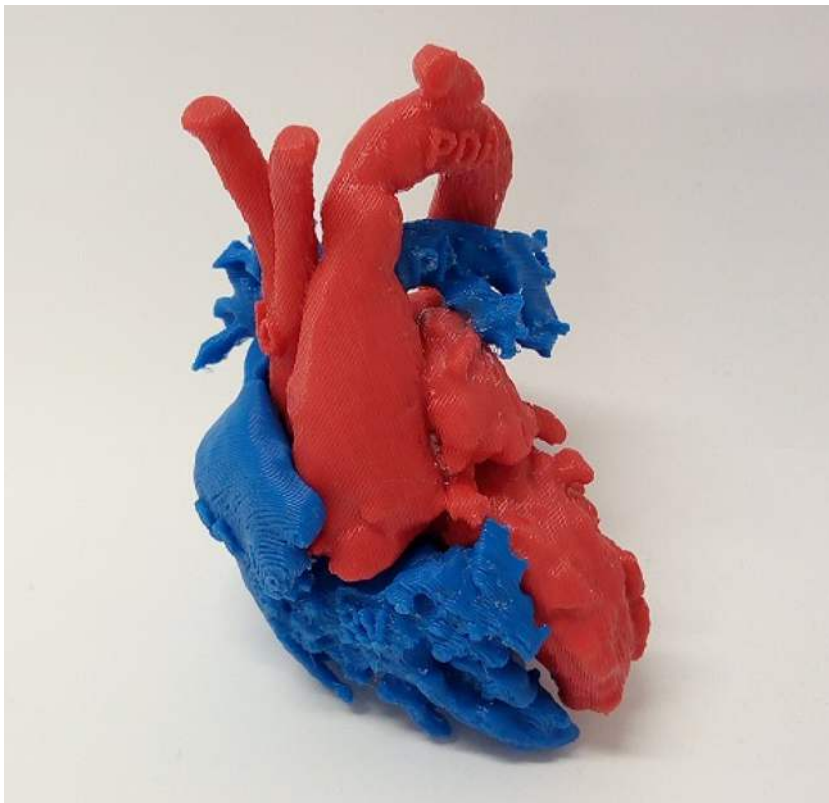


CARDIOLOGICAL POST-SURGICAL REVIEW

SPECIALITY: CARDIOLOGY

PROCEDURE: TRUNCUS ARTERIOSUS AND INTERRUPTED AORTIC ARCH REPAIR

DEVICE: 3D PRINTED PATIENT-SPECIFIC ANATOMICAL MODEL



OUTCOME / BENEFITS

3D modelling and printing of complex pathologies such as this provide an effective adjunct to traditional surgical education and skill development methods. Rare cases can be captured for repeatable future training, ensuring high level knowledge is transferred through a medium that combines 3D visualisation with haptics.

The model's use in conversations with the patient's parents allowed for more detailed explanation and understanding, meaning the parents were more informed about their child's condition and what future treatments would involve.

CASE SUMMARY

Alongside using patient-specific anatomical models for pre-surgical planning, cardiology departments often use Insight Surgery's on-site service to capture rare and complex congenital cases for educational and training purposes on a regular basis.

The surgeon requested this patient-specific model to better educate current colleagues and future cardiologists at the hospital.

DESCRIPTION

In this case, the patient was diagnosed with hypoplastic left heart syndrome (HLHS), had undergone an atrial septectomy, bilateral pulmonary artery (PA) banding and insertion of a patent ductus arteriosus (PDA) stent.

Insight Surgery segmented the patient's scan data and worked closely with the cardiologist, in Insight Surgery's hub within the hospital, to produce a virtual model optimised for clear demonstrations. The virtual model was then 3D printed in soft material for a more realistic feel.


INSIGHT SURGERY CASE STUDY

PEDIATRIC CARDIOLOGICAL EDUCATION & TRAINING

SPECIALITY: CARDIOLOGY

PROCEDURE: ATRIAL SEPTECTOMY, BILATERAL PA BANDING & PDA

DEVICE: 3D PRINTED PATIENT-SPECIFIC ANATOMICAL MODEL



OUTCOME / BENEFITS

The use of 3D printed models serve as an adjunct to the department's traditional education and training methods, such as 2D CT Angiogram, CT or MRI scan interpretation. Accurate physical models allow 360-degree haptic manipulation for a more complete visualisation of the congenital heart defect by the handler.

With the model, the cardiologist is able to better explain the nature of the pathology, its effect on the patient, the treatment paths available, and the specific approach chosen in a particular case.

CASE SUMMARY

Alongside using patient-specific anatomical models for pre-surgical planning, the cardiology department at a children's hospital also uses Insight Surgery's on-site service to capture rare and complex congenital cases for educational and training purposes on a regular basis.

A cardiologist requested this patient-specific model to better educate current colleagues and future cardiologists at the hospital.

DESCRIPTION

In this case, the patient presented with multiple congenital defects, including; double outlet right ventricle (DORV), transposition of the great arteries (TGA), ventricular septal defect (VSD) and a Taussig-Bing anomaly.

Insight Surgery segmented the patient's scan data and worked closely with the cardiologist, in Insight Surgery's hub within the hospital, to produce a virtual model optimised for clear demonstrations. The virtual model was then 3D printed in soft material for a more realistic feel.

INSIGHT SURGERY CASE STUDY

PEDIATRIC CARDIOLOGICAL EDUCATION AND TRAINING

SPECIALITY: CARDIOLOGY

PROCEDURE: TREATMENT FOR DORV, TGA, VSD, TAUSSIG BING

DEVICE: 3D PRINTED PATIENT-SPECIFIC ANATOMICAL MODEL



OUTCOME / BENEFITS

The use of 3D printed models serve as an adjunct to the department's traditional education and training methods, such as 2D CT Angiogram, CT or MRI scan interpretation. Accurate physical models allow 360-degree haptic manipulation for a more complete visualisation of the congenital heart defect by the handler.

With the model, the cardiologist is able to better explain the nature of the pathology, its effect on the patient, the treatment paths available, and the specific approach chosen in a particular case.

CASE SUMMARY

Alongside using patient-specific anatomical models for pre-surgical planning, the cardiology department at a children's hospital also use Insight Surgery's on-site service to capture rare and complex congenital cases for educational and training purposes on a regular basis.

A cardiologist requested this patient-specific model to better educate current colleagues and future cardiologists at the hospital.

DESCRIPTION

In this case, the patient presented with hypoplastic left heart syndrome with anomalous coronary artery originating from the main pulmonary artery, an extremely rare congenital defect which poses one of the highest levels of risk of severe ischemia or even myocardial infarction, dangerous arrhythmias, chronic circulatory failure and sudden death.

Insight Surgery segmented the patient's scan data and worked closely with the cardiologist, in Insight Surgery's hub within the hospital, to produce a virtual model optimised for clear demonstrations. The virtual model was then 3D printed in soft material for a more realistic feel.

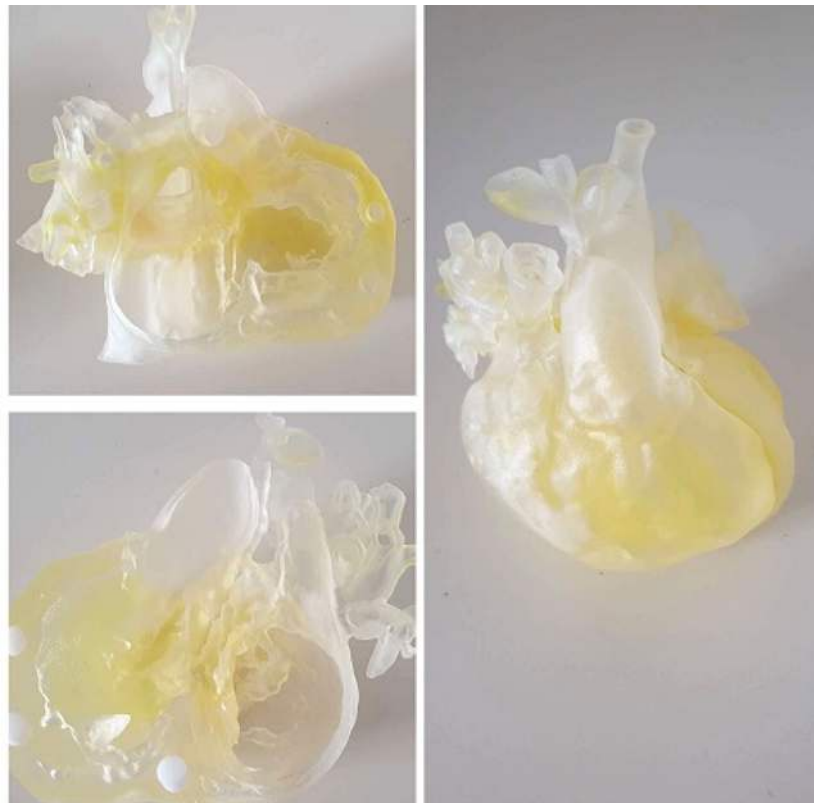
INSIGHT SURGERY CASE STUDY

PEDIATRIC CARDIOLOGICAL EDUCATION AND TRAINING

SPECIALITY: CARDIOLOGY

PROCEDURE: HLHS WITH ANOMALOUS CORONARY ARTERY FROM MPA

DEVICE: 3D PRINTED PATIENT-SPECIFIC ANATOMICAL MODEL



OUTCOME / BENEFITS

The use of 3D printed models serve as an adjunct to the department's traditional education and training methods, such as 2D CT Angiogram, CT or MRI scan interpretation. Accurate physical models allow 360-degree haptic manipulation for a more complete visualisation of the congenital heart defect by the handler.

With the model, the cardiologist is able to better explain the nature of the pathology, its effect on the patient, the treatment paths available, and the specific approach chosen in a particular case.

CASE SUMMARY

Alongside using patient-specific anatomical models for pre-surgical planning, cardiology departments also use Insight Surgery's on-site service to capture rare and complex congenital cases for educational and training purposes on a regular basis.

The surgeon requested this patient-specific model to better educate current colleagues and future cardiologists at the hospital.

DESCRIPTION

In this case, the patient presented with a previous interrupted arch and small left ventricular outflow tract (LVOT). The patient had previously undergone a Norwood procedure and cavopulmonary anastomosis.

Insight Surgery segmented the patient's scan data and worked closely with the cardiologist, in Insight Surgery's hub within the hospital, to produce a virtual model optimised for clear demonstrations. The virtual model was then 3D printed in a soft material for a more realistic feel.

INSIGHT SURGERY CASE STUDY

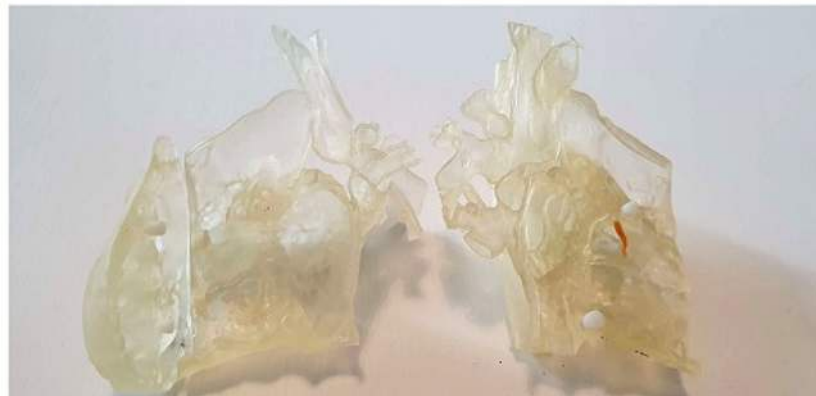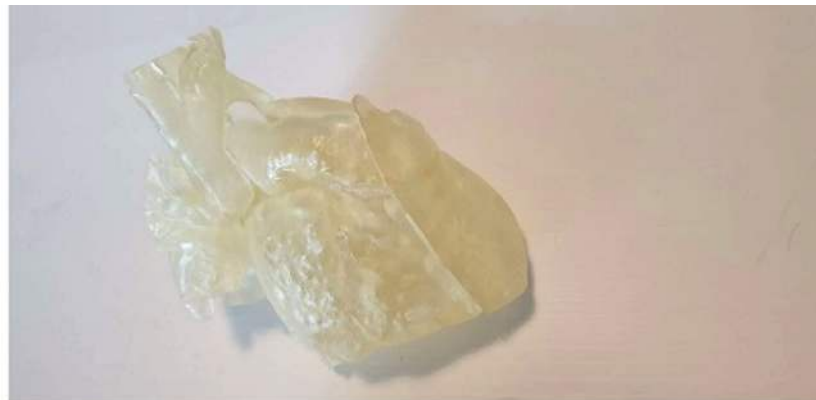


PEDIATRIC CARDIOLOGY EDUCATION & TRAINING

SPECIALITY: CARDIOLOGY

PROCEDURE: PREVIOUS INTERRUPTED ARCH & SMALL LVOT, NORWOOD PROCEDURE

DEVICE: 3D PRINTED PATIENT-SPECIFIC ANATOMICAL MODEL



OUTCOME / BENEFITS

The use of 3D printed models serve as an adjunct to the department's traditional education and training methods, such as 2D CT Angiogram, CT or MRI scan interpretation. Accurate physical models allow 360-degree haptic manipulation for a more complete visualisation of the congenital heart defect by the handler.

With the model, the cardiologist is able to better explain the nature of the pathology, its effect on the patient, the treatment paths available, and the specific approach chosen in a particular case.

CASE SUMMARY

Cardiologists at a children's hospital were inspired to explore the use of 3D modelling and printing as a way to bring their CT angiograms of pre and postnatal patients to life.

Converting the scans, made during diagnostic investigations into anti and post-natal aortic abnormalities, into 3D models proved to be a useful adjunct to traditional CT angiogram interpretation and use in communication with others involved with the patient's treatment. Explanation of the pathology and challenges inherent to each treatment pathway became much clearer in their conveyance.

DESCRIPTION

In this model, the main artery (pink) presents on the right-hand side of the patient's body, instead of the more common left-hand side. This is a right aortic arch. As the aorta descends, it joins other structures, such as the ductus ligament and the pulmonary artery, in encircling the trachea and oesophagus which can lead to breathing and feeding problems.

In terms of surgical planning, the decision to make is whether to divide the ductal ligament or consider removing the whole of the Kommerell diverticulum. The challenge in conducting surgery in an older patient such as this is that surgeons run the risk of compromising blood flow to the left arm. Earlier intervention could have created co-lateral blood supply, preventing the risk.

INSIGHT SURGERY CASE STUDY

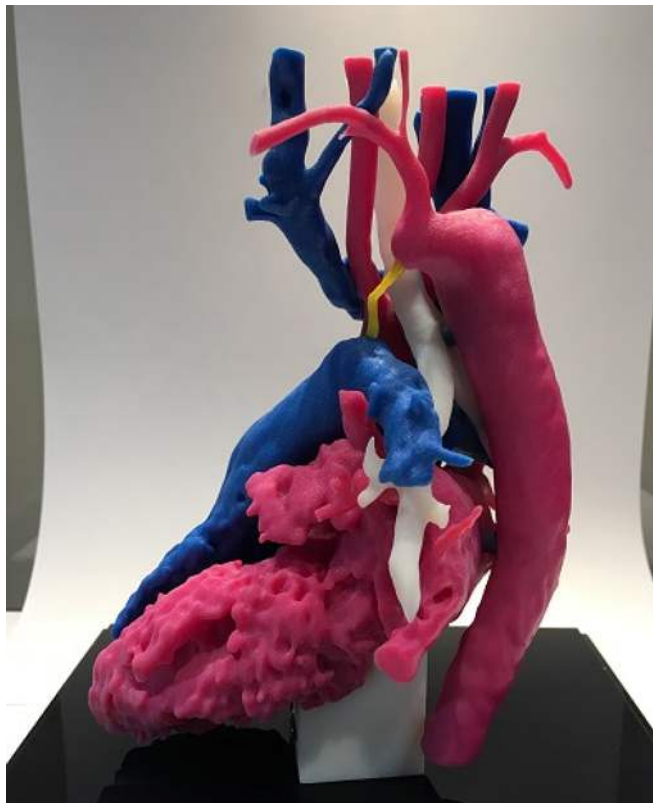


PEDIATRIC CARDIOTHORACIC EDUCATION AND TRAINING

SPECIALITY: CARDIOLOGY

PROCEDURE: INVESTIGATION INTO ANTI AND POST-NATAL AORTIC ARCH ABNORMALITIES

DEVICE: 3D PRINTED PATIENT-SPECIFIC ANATOMICAL MODELS



OUTCOME / BENEFITS

Over time, a collection of models has been built to aid understanding and education at the hospital and is beginning to form part of a standardised pathway into aortic arch investigation. In each case, the model acts as a focal point for surgeons as they set out procedure choices to colleagues.

Particular value has also been found in their explanatory power for junior clinicians and surgeons still in training, as well as for patient families who benefit from a clear representation of what their child faces, what the proposed treatment pathway will be, and why it was chosen in their case.

Case Summary

Cardiologists at a children's hospital were inspired to explore the use of 3D modelling and printing as a way to bring their CT angiograms of pre and postnatal patients to life.

Converting the scans, made during diagnostic investigations into anti and post-natal aortic abnormalities, into 3D models proved to be a useful adjunct to traditional CT angiogram interpretation and use in communication to others involved with the patient's treatment. Explanation of the pathology and challenges inherent to each treatment pathway became much clearer in their conveyance.

Description

In this model, there is a true double aortic arch developing which is another condition which can lead to pressure on the trachea and oesophagus.

The main artery comes out of the heart and divides in two. Surgeons must make the decision of which arch to split. In this case the smaller right arch was chosen, creating room for the trachea and oesophagus to grow without hindrance.

INSIGHT SURGERY CASE STUDY

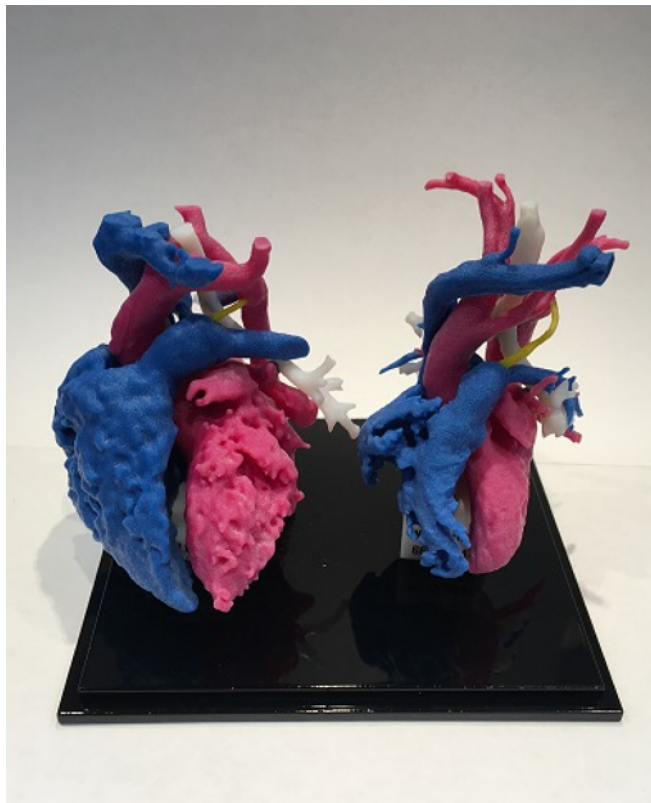


PEDIATRIC CARDIOTHORACIC EDUCATION AND TRAINING

SPECIALITY CARDIOLOGY

PROCEDURE INVESTIGATION INTO ANTI AND POST-NATAL AORTIC ARCH ABNORMALITIES

DEVICE 3D PRINTED PATIENT-SPECIFIC ANATOMICAL MODELS



OUTCOME / BENEFITS

Over time, a collection of models has been built to aid understanding and education at the hospital and is beginning to form part of a standardised pathway into aortic arch investigation. In each case, the model acts as a focal point for surgeons as they set out procedure choices to colleagues.

Particular value has also been found in their explanatory power for junior clinicians and surgeons still in training, as well as for patient families who benefit from a clear representation of what their child faces, what the proposed treatment pathway will be, and why it was chosen in their case.

Case Summary

Cardiologists at a children's hospital were inspired to explore the use of 3D modelling and printing as a way to bring their CT angiograms of pre- and postnatal patients to life.

Converting the scans, made during diagnostic investigations into anti and post-natal aortic abnormalities, into 3D models proved to be a useful adjunct to traditional CT angiogram interpretation and use in communication to others involved with the patient's treatment. Explanation of the pathology and challenges inherent to each treatment pathway became much clearer in their conveyance.

Description

In this model, the aorta, which usually forms an arch in the chest that travels inside the chest on the left side, is found on the right, known as a right aortic arch. A Kommerell diverticulum is also present in this very young patient. Their ductus arteriosus had also failed to close post-natally, depicted in the model by the purple structure.

This model helps demonstrate what can happen when a double aortic arch, a condition all babies experience during pregnancy until conditions establish a dominant arch, forms on the right-hand side instead of the left.

INSIGHT SURGERY CASE STUDY

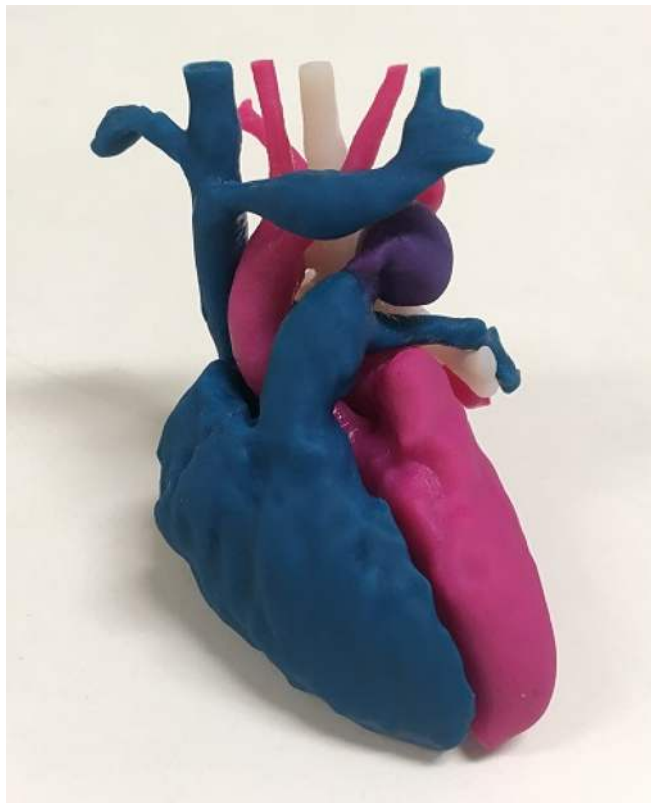


CARDIOLOGY EDUCATION & TRAINING

SPECIALITY CARDIOLOGY

PROCEDURE INVESTIGATION INTO ANTI & POST-NATAL AORTIC ARCH ABNORMALITIES

DEVICE 3D PRINTED PATIENT-SPECIFIC ANATOMICAL MODELS



OUTCOME / BENEFITS

Over time, a collection of models has been built to aid understanding and education at Evelina and is beginning to form part of a standardised pathway into aortic arch investigation. In each case, the model acts as a focal point for surgeons as they set out procedure choices to colleagues.

Particular value has also been found in their explanatory power for junior clinicians and surgeons still in training, as well as for patient families who benefit from a clear representation of what their child faces, what the proposed treatment pathway will be, and why it was chosen in their case.

CASE SUMMARY

A Consultant Pediatric Cardiologist requested 20 3D printed heart models to be used as part of a professional education course exploring Fetal Cardiology, MRI and Echocardiography.

In particular, the identification of congenital heart defects and treatment options were to be discussed.

DESCRIPTION

All models were printed in soft material for a more life-like handling experience. In some cases, inserts for small magnets were designed into the prints.

The use of small magnets embedded within the printed sections allowed for the models to be taken apart and reassembled. This enabled interior perspectives of the congenital defects the models were portraying for the attendees.

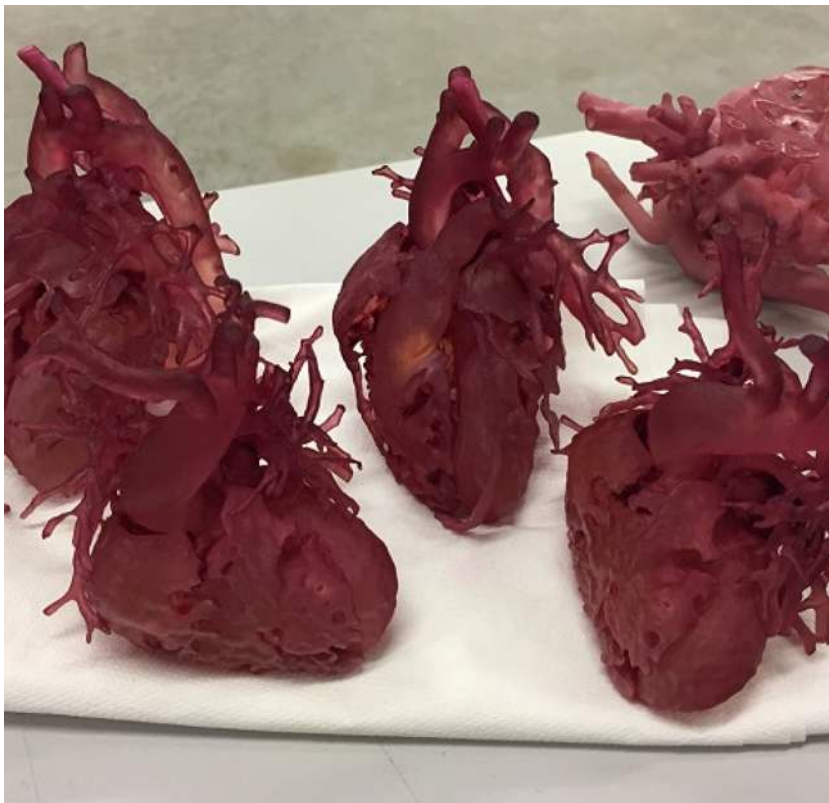INSIGHT SURGERY CASE STUDY

PEDIATRIC CARDIOLOGICAL EDUCATION & TRAINING

SPECIALITY: CARDIOLOGY

PROCEDURE: CONGENITAL HEART DEFECT IDENTIFICATION AND TREATMENT

DEVICE: 3D PRINTED PATIENT-SPECIFIC ANATOMICAL MODELS



OUTCOME / BENEFITS

The 20 heart models, some of which could be taken apart and pieced together again, provided attendees with realistic, tactile teaching aids that could be passed around and explored as an adjunct to lectures and screen-based learning which formed the majority of the course. Combining haptics with visual learning is increasingly being seen as a more effective approach to teaching clinicians about complex pathologies and treatments than visual instruction alone.

The models are durable enough to be used for repeat courses in years to come, allowing the hospital to continue to deliver leading cardiac training to professionals from around the world.

CASE SUMMARY

A cardiac surgeon at a children's hospital requested a 3D printed anatomical model for an educational demonstration of surgical simulation at the Arab Health Exhibition in Dubai, 2017, held to showcase products from the medical and pharmaceutical industries.

DESCRIPTION

The heart model for this simulation was 3D printed in silicone and intentionally softened to replicate the consistency of an infant's cardiac tissue.

The model was nested in a set of 3D printed ribs to further increase the sense of realism for the surgeon and attendees. This simulation included the closure of an atrial septal defect (ASD) and widening of the pulmonary stenosis on the 3D printed heart.

The surgeon encouraged participation from the attendees, and several of them were able to practice the suturing techniques necessary for this procedure.

INSIGHT SURGERY CASE STUDY

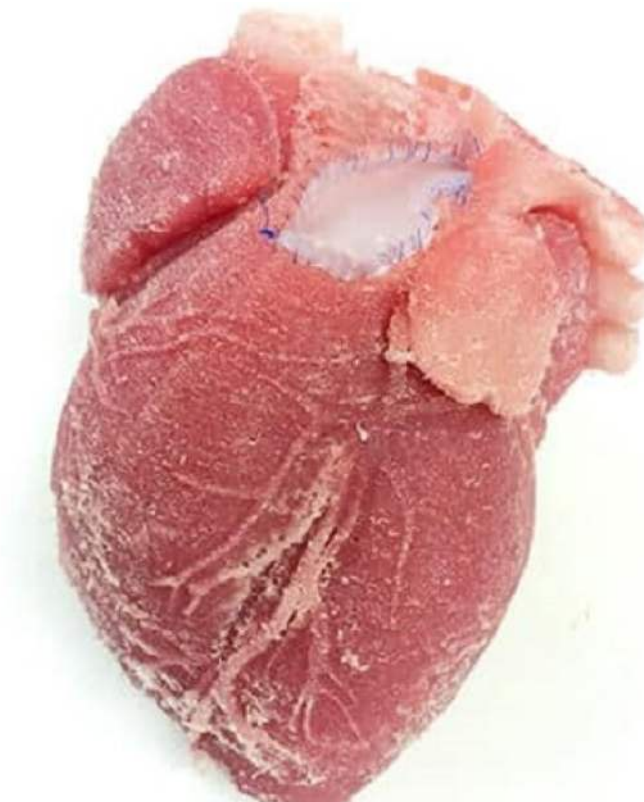

PEDIATRIC CARDIOLOGICAL SURGICAL SIMULATION AND TRAINING

SPECIALITY: CARDIOLOGY

PROCEDURE: REPAIR OF CONGENITAL HEART DEFECTS

DEVICE: 3D PRINTED PATIENT-SPECIFIC ANATOMICAL SIMULATION MODEL



OUTCOME / BENEFITS

As 3D print material options continue to improve, the levels of haptic realism for surgical departments looking to use 3D printed models for simulator-based training increases.

The use of 3D printed models for surgical training is on the rise due to barriers such as legality, cost and availability in the use of cadaveric models. 3D models avoid any such issues and come with the benefit of being completely customisable, not only in terms of model scale and material, but in terms of complex pathologies being available for on demand replication.

This is highly useful for training individuals in more advanced procedures for patients presenting with complex or rare conditions, such as congenital heart defects.

CASE SUMMARY

A cardiac surgeon requested two patient-specific 3D printed cardiac models so that they could demonstrate the complex Senning procedure as part of a double switch operation for congenitally corrected transposition of the great arteries (TGA), to surgical trainees and other clinicians with great levels of realism.

DESCRIPTION

The first model (left) represented a hollow heart and therefore captured both the external and internal patient-specific morphology of the heart, as a result of Insight Surgery's engineer subtracting the blood volume from it. It was then printed in soft, translucent material proving effective for surgeons looking to simulate surgery.

The second model (right) represented the blood volume and therefore offered unparalleled visualisation of how the internal chambers and main vessels are affected by TGA. The model was printed in rigid material as it was used for visual reference only.

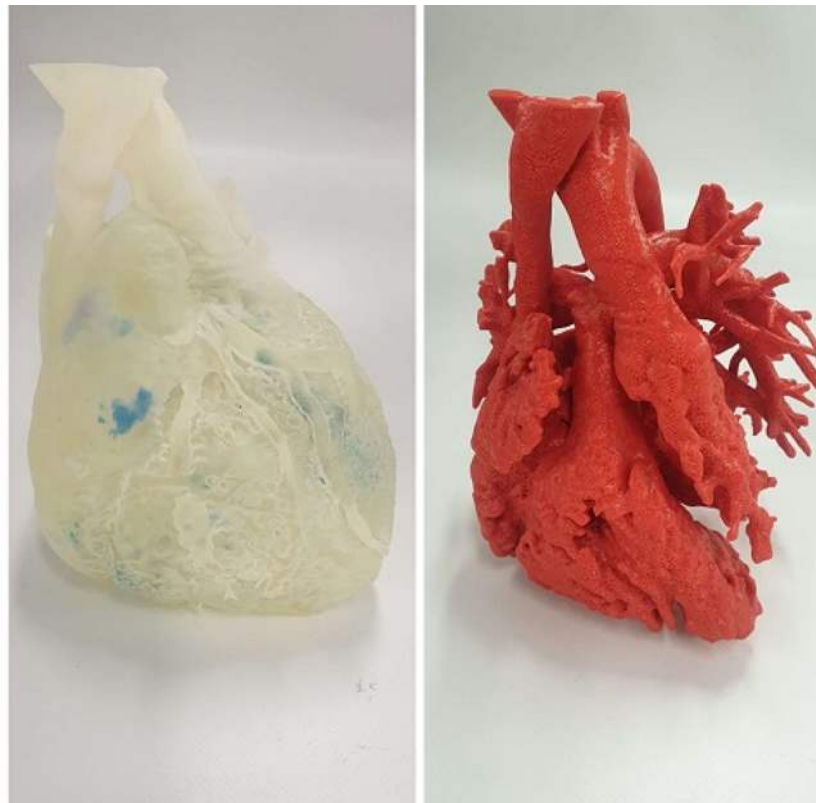
INSIGHT SURGERY CASE STUDY

CARDIOTHORACIC EDUCATION AND TRAINING

SPECIALITY: CARDIOLOGY

PROCEDURE: SIMULATION AND TEACHING OF THE SENNING PROCEDURE

DEVICE: 3D PRINTED PATIENT-SPECIFIC ANATOMICAL MODELS



OUTCOME / BENEFITS

The cardiac surgeon was able to use both models to effectively showcase the effects of TGA to both students and professionals about the condition.

The surgeon also performed a simulation of the Senning procedure on the translucent model, after which both models will remain as a permanent reference tool for future professional education.

A collection of various 3D printed cardiac models, including hearts, valves, and complex vascular structures, displayed on a white surface. The models are semi-transparent, revealing internal structures. In the background, a box of 'vitality' brand tissues is partially visible.

CARDIAC SOLUTIONS



WE PRIDE OURSELVES
ON PROVIDING
OUTSTANDING CLIENT
SERVICE, AND ARE
ALWAYS AVAILABLE FOR
A DISCUSSION

EMAIL US
info@insightsurgery.com

CALL US
+1 281 733 2568 (Houston office)
+44 (0) 151 528 8749 (Liverpool
office)
+44 (0) 1865 52 2767 (Oxford
office)
+44 (0) 207 193 5630 (London
office)

Texas Medical Center
2450 Holcombe Blvd, Suite X,
Houston, Tx 77021, USA

Alder Hey Children's Hospital
Eaton Road, Liverpool L12 2AP, UK

Nuffield Orthopaedic Centre
Old Road, Oxford OX3 7LD, UK

Wrightington Hospital
Hall Lane, Appley Bridge, Wigan
WN6 9EP, UK

Leeds General Infirmary
Gilbert Scott Building, Leeds, LS1
3EX, UK

