



CMF SURGERY SOLUTIONS

3D PLANNING, PATIENT-SPECIFIC
ANATOMICAL MODELS, SURGICAL
GUIDES AND PATIENT-SPECIFIC
IMPLANTS

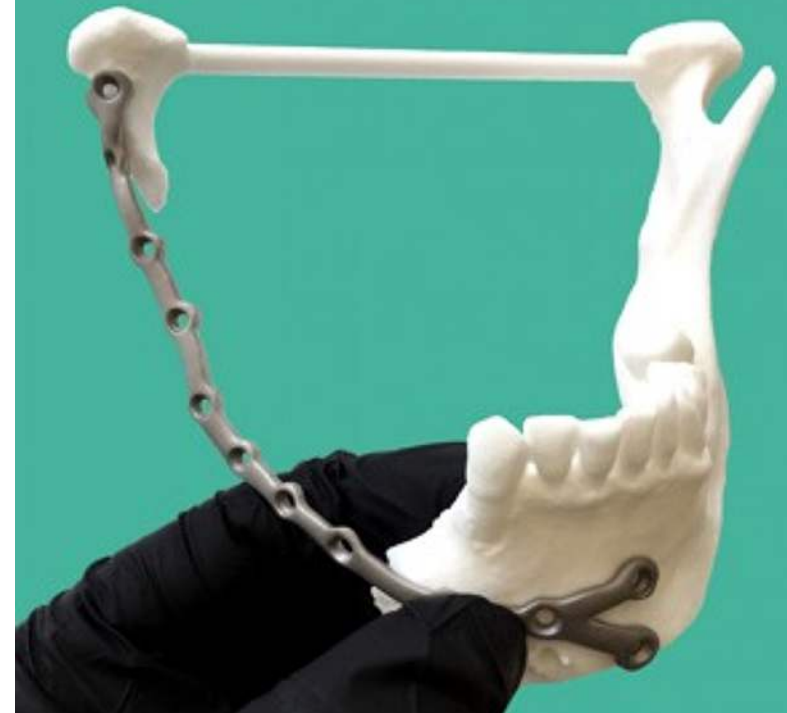SUMMARY / INDEX

CMF SURGERY

- Head & Neck reconstruction
- Trauma
- Complex deformities
- Orthognathic surgery
- Aesthetic surgery

3D PRINTED IMPLANTS/SURGICAL GUIDES

- Cutting and drilling guides
- Cranioplasty
- Orbital floor implant
- Reconstruction plate
- Osteosynthesis plate



CASE SUMMARY

This patient presented with severe facial asymmetry (of both the mandible and maxilla) and a class III occlusion. The patient had a yaw, with their mandible swinging to the left, and the mandibular midline was off to the left by 4mm.

The surgeon requested two patient-specific anatomical models to assist with the pre-surgical planning and simulation ahead of the orthognathic surgery.

DESCRIPTION

Insight Surgery received the patient's CT scan in DICOM format and proceeded to segment the full skull.

Two anatomical models were provided to the surgeon. The first was printed in clear resin with multicolour used to highlight the roots of the teeth and mental nerves. This would be used for careful planning of the osteotomies.

The second model was printed in a wood-like material to allow for full procedural simulation as well as pre-bending of implant plates ahead of live surgery.

INSIGHT SURGERY CASE STUDY

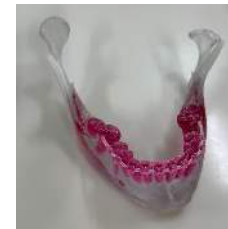
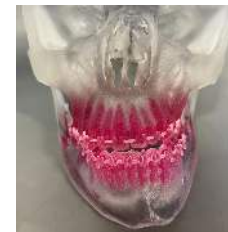
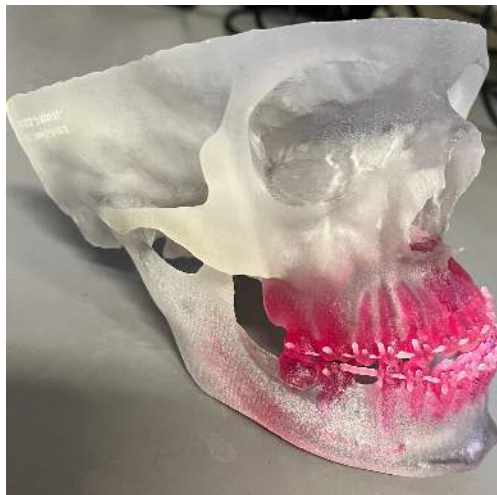ORTHOGNATHIC PRE-SURGICAL PLANNING, SIMULATION, PLATE BENDING

SPECIALITY: ORTHOGNATHIC

PROCEDURE: LE FORT I, BSSO

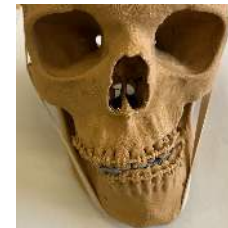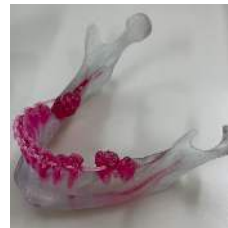DEVICE: 3D PRINTED PATIENT-SPECIFIC ANATOMICAL MODELS



OUTCOME / BENEFITS

These models will support careful pre-operative planning of the surgeon's cuts, with the model highlighting the nerves and teeth roots providing particular guidance.

Simulation on the wood-like model will translate to time saved in theatre, as will the pre-bending of plates using the anatomically correct device. With the plates already bent to the patient's anatomy, a better aesthetic outcome is expected.



CASE SUMMARY

Cancer treatment had resulted in osteoradionecrosis (bone death due to radiation) in a patient and complex mandible reconstruction was necessary. Fibula free flap surgical reconstruction was required whereby the patient's fibula is removed and reshaped before being used to recreate the jaw.

Surgeons requested 3D printed cutting guides to be designed and manufactured for both fibula and mandible bones.

DESCRIPTION

3D segmentation and reconstruction were used to create patient-specific anatomical models. These models were in turn used to:

- Virtually plan the surgery, allowing surgeons to determine the resection of the mandible and the reshaping of the fibula into a new mandible and;
- As templates to design the patient-specific cutting guides and reconstruction plate which secured the bone segments in place.

The patient-specific guides were printed using medical-grade nylon polyamide while the mandible plate was produced using titanium. All were sterilized using autoclaving.

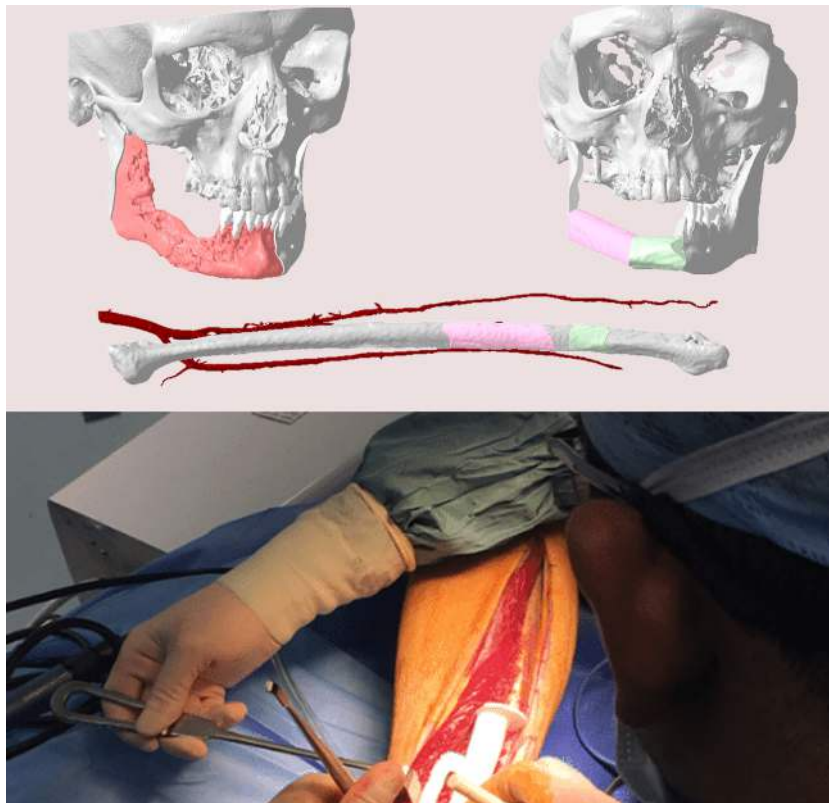
INSIGHT SURGERY CASE STUDY

CRANIO-MAXILLOFACIAL RECONSTRUCTION

SPECIALITY: CRANIO-MAXILLOFACIAL

PROCEDURE: FIBULA FREE FLAP RECONSTRUCTION

DEVICES: 3D PRINTED PATIENT-SPECIFIC GUIDES AND IMPLANT



OUTCOME / BENEFITS

With the use of 3D technologies, the surgeons were able to avoid the typical, time-consuming procedure in which a straight metal plate is bent to fit the reconstruction.

The use of pre-designed and manufactured patient-specific plates meant the risk of compromised surgery, caused by prolonged disruption of blood supply to the fibula bone while the plate is being shaped in traditional surgery, was also avoided.

The surgery was a success, with both guides and implant fitting perfectly, and no further adaptation was required during the procedure.

CASE SUMMARY

The surgeon approached Insight Surgery for assistance in the treatment of a patient following the surgical removal of a right sinus cyst. Reconstruction of the right orbital floor, which seemed resorbed, was necessary.

Insight Surgery was asked to produce a patient-specific anatomical model of the patient's orbits and zygoma for Royal Free Hospital, to use in their pre-surgical planning.

DESCRIPTION

Insight Surgery segmented the patient's CT scan to produce a virtual model of the orbital bone structure and sinuses. It was then printed using PA12, a rigid material which can be sterilised for intraoperative use.

This model was used in the pre-planning phase, during which the surgeon bent a standard orbital floor implant on the model.

The implant, adapted to the patient's anatomy, was then sterilised and implanted during the surgery. The model was also brought into theatre, to be used as a reference to help with implant positioning.

INSIGHT SURGERY CASE STUDY

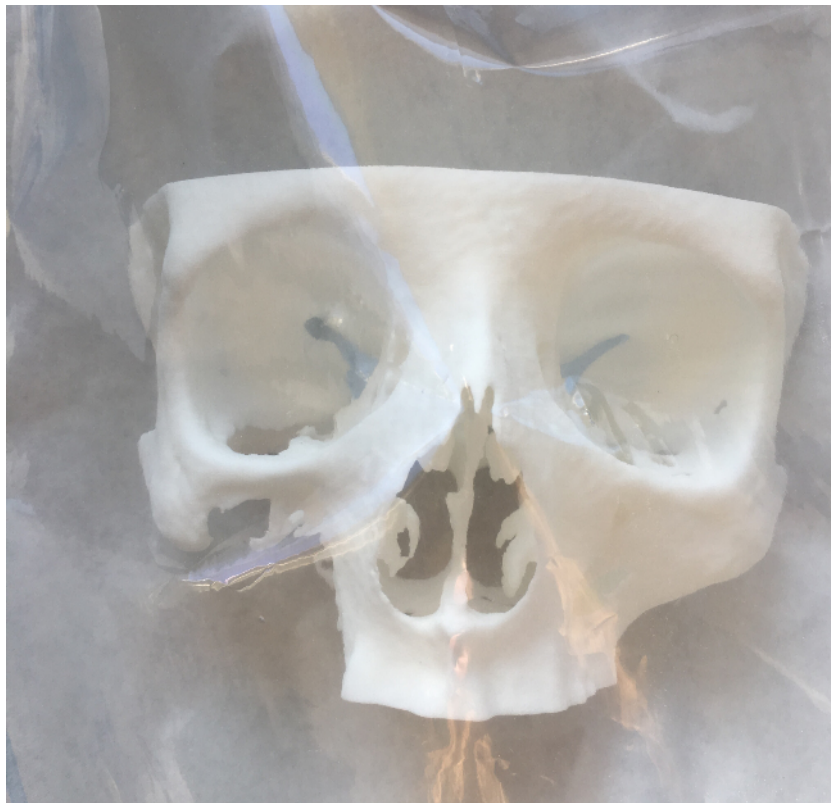

CRANIO-MAXILLOFACIAL PRE-SURGICAL PLANNING

SPECIALITY: CRANIO-MAXILLOFACIAL

PROCEDURE: ORBITAL FLOOR RECONSTRUCTION

DEVICES: 3D PRINTED PATIENT-SPECIFIC ANATOMICAL MODEL



OUTCOME / BENEFITS

Being able to visualise the patient's anatomy and adapt a standard implant onto it prior to surgery not only allowed surgeons to fully anticipate and plan the extent and complexity of surgery required, but also reduced surgery time.

CASE SUMMARY

A patient diagnosed with an odontogenic myxoma, a rare and locally aggressive tumour, needed a resection of their mandible followed by a microvascular reconstruction with DCIA. In this case, the entire part of the mandible was rebuilt using bone from the patient's hip with microvascular anastomosis.

To ensure that the inferior alveolar nerve on both sides of the patient's mandible was not damaged during the resection and that the choice of bone from the iliac crest was a custom fit, the clinic reached out to Insight Surgery for assistance in the creation of several patient-specific devices that would help ensure the best possible outcome for the patient.

DESCRIPTION

Insight Surgery's biomedical engineer segmented the patient's CT scan to produce a virtual model of the patient's cranial and pelvic anatomy.

In collaboration with the surgeon, optimum planes for resection were found through conducting a virtual surgery. These cutting planes were then translated into custom surgical guides which would enable the surgical team to replicate the desired cuts in theatre.

The guides were printed in sterilisable material and delivered to the hospital for autoclaving.

INSIGHT SURGERY CASE STUDY

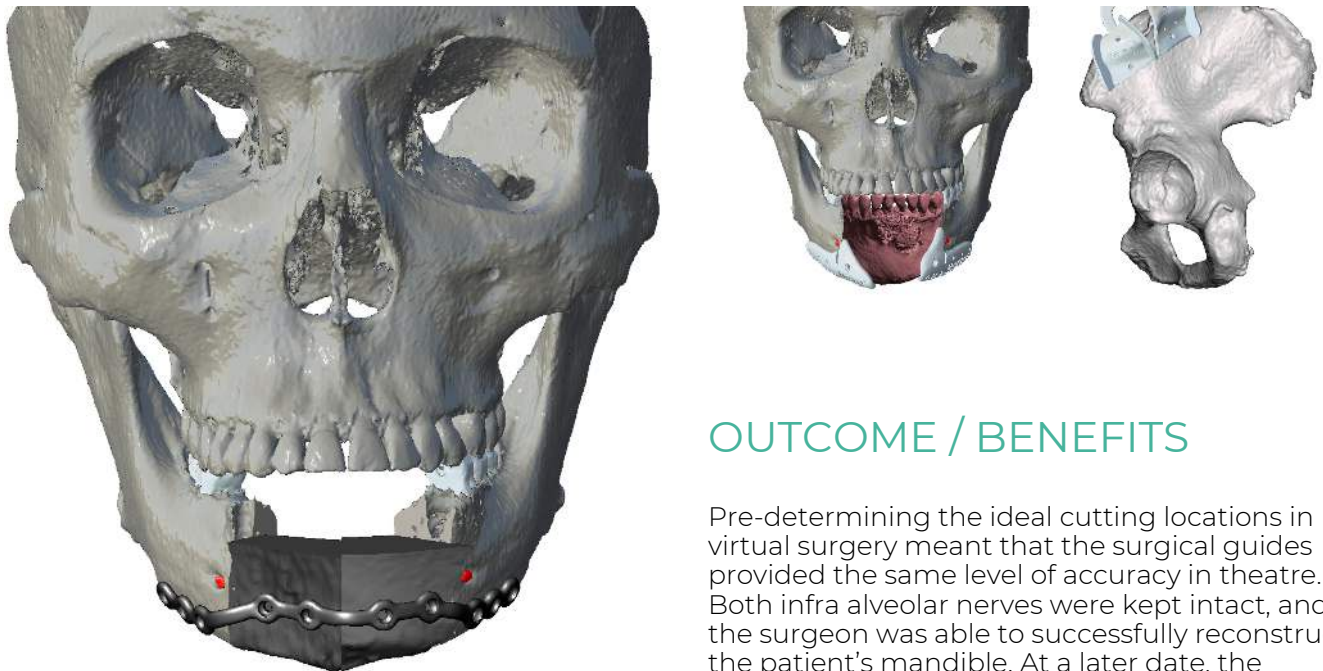

CRANIO-MAXILLOFACIAL PRE-SURGICAL PLANNING, SURGICAL GUIDES AND IMPLANT

SPECIALITY: CRANIO-MAXILLOFACIAL

PROCEDURE: ANTERIOR MANDIBLE RESECTION AND MICROVASCULAR RECONSTRUCTION

DEVICES: 3D PRINTED PATIENT-SPECIFIC ANATOMICAL MODELS, SURGICAL GUIDES AND IMPLANT



OUTCOME / BENEFITS

Pre-determining the ideal cutting locations in virtual surgery meant that the surgical guides provided the same level of accuracy in theatre. Both infra alveolar nerves were kept intact, and the surgeon was able to successfully reconstruct the patient's mandible. At a later date, the patient will have implants and a fixed dental prosthesis fitted as part of her treatment.

CASE SUMMARY

The surgeon approached Insight Surgery for assistance in preparation for a tumour removal surgery for a patient presenting with a growth that compromised their frontal sinus, amongst other structures. Following excision, reconstruction of the frontal bone would also be required, using bone taken from other areas of the patient's anatomy.

Two models were requested to help surgeons fully visualise and plan their approach to both procedures; resection and reconstruction.

DESCRIPTION

Insight Surgery segmented the patient's data and constructed virtual models of their anatomy. A transparent 3D printed skull was printed to show the position of the patient's tumour in relation to the frontal sinus.

Full-scale replicas of the patient's 6th and 7th ribs, as well as the left scapula, were also printed. These models were used to help the surgeons evaluate how best to reconstruct the frontal bone. It was printed in woodfill, a bonelike material, for a more realistic haptic feel.

INSIGHT SURGERY CASE STUDY

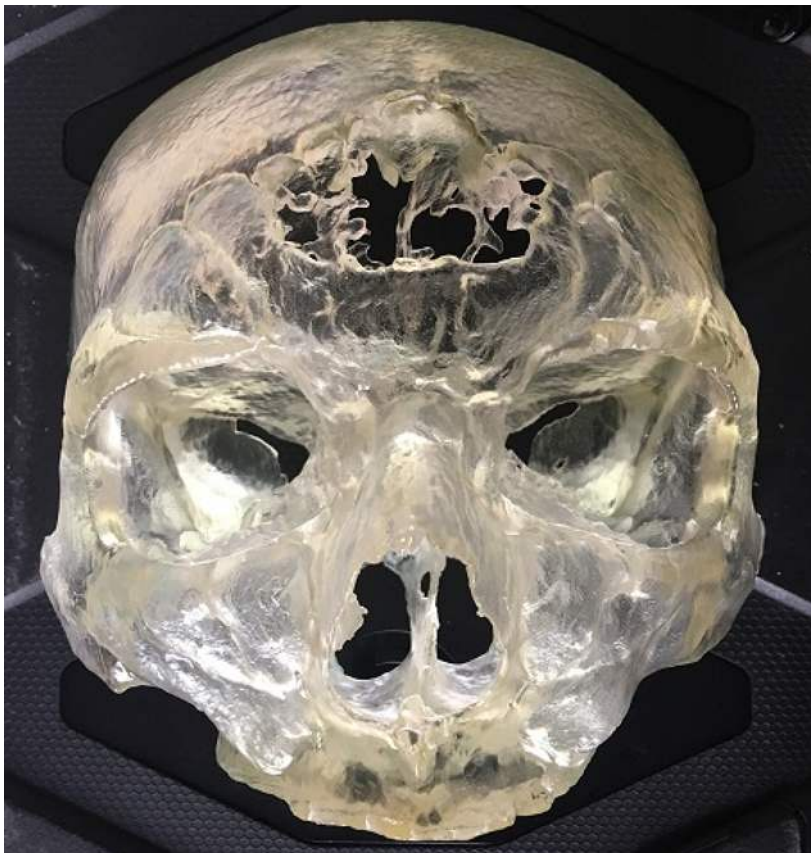

CRANIO ONCOLOGICAL PRE-SURGICAL PLANNING AND INTRA-OPERATIVE REFERENCE

SPECIALITY: CRANIO-MAXILLOFACIAL

PROCEDURE: MANDIBULAR RECONSTRUCTION WITH SCAPULA FLAP

DEVICES: 3D PRINTED PATIENT-SPECIFIC ANATOMICAL MODEL, SURGICAL GUIDES AND IMPLANT



OUTCOME / BENEFITS

Surgeons at the hospital were able to more effectively plan their tumour-removal surgery ahead of the live procedure.

The transparent material provided a clear view of the location of the tumour and a new perspective on how best to proceed in relation to the bone that would require subsequent reconstruction.

Surgeons were able to successfully gauge the most appropriate size and areas of bone to cut from the ribs and scapula for use in the reconstruction of the frontal bone following removal of the cranial tumour.

CASE SUMMARY

The failure of a previous mandible reconstruction meant that this patient needed revision surgery. The old flap had to be removed and only the old plate remained for support. A second reconstructive attempt was vital. However, effective surgery would be challenging, as the quality of the remaining mandible bone was extremely poor. Securing the implant's plate screws would be difficult.

The surgeon requested assistance from Insight Surgery for the pre-surgical planning, the creation of an anatomical model, surgical cutting guides and a custom plate for the patient's unique anatomy.

DESCRIPTION

Insight Surgery segmented the patient's CT scan and created the virtual model for the surgeon to identify the ideal cutting planes at each location. From these, 3D printed surgical guides and a titanium reconstruction plate were designed and manufactured, as were the anatomical models for reference purposes.

Two guides were provided; for the mandible and chin, and for the scapula to raise the flap for the reconstruction. They were printed in Polyamide/PA 12. The custom plate used to secure the flap was printed in titanium.

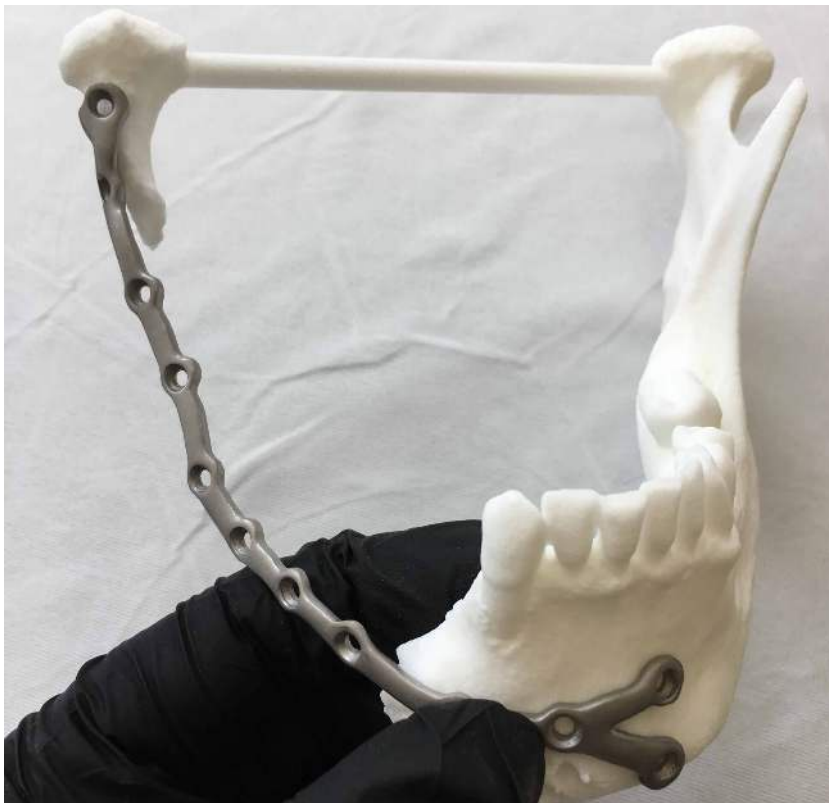INSIGHT SURGERY CASE STUDY

CRANIO-MAXILLOFACIAL PRE-SURGICAL PLANNING, SURGICAL GUIDES, AND IMPLANT

SPECIALITY: CRANIO-MAXILLOFACIAL

PROCEDURE: RECONSTRUCTION WITH SCAPULA FREE FLAP

DEVICES: 3D PRINTED PATIENT-SPECIFIC ANATOMICAL MODELS, SURGICAL GUIDES AND IMPLANT



OUTCOME / BENEFITS

Thanks to the digital planning, it was possible to determine the areas of the mandible and chin which had the greatest integrity for the placement of the screws. The surgical guides used in theatre enabled the successful avoidance of holes drilled previously, maintaining the patient's bone integrity and securing the new 3D printed reconstruction plate in position.

A 3D printed model of the patient's anatomy was also used intra-operatively as a reference guide for the surgeon. The reconstruction and the implantation of the custom implant were carried out without complication and dental rehabilitation is being planned for the patient's future without complication.

CASE SUMMARY

ENT researchers, who were investigating the sinus treatment of a paediatric patient, requested an anatomically correct model for testing the flow and coverage of nasal spray solutions as part of their research.

DESCRIPTION

Insight Surgery segmented the test subject's CT scan data and provided a model of their bony facial structures with accompanying voids and sinuses. Bony structures were printed in a rigid PLA, while the voids & sinuses were lined with a layer of flexible silicon to represent the soft tissue properties found in these locations. The model also had strategically placed holes drilled into it, to allow for the insertion of a camera into the internal cavities while sinuses were being flushed.

The investigators sprayed their nasal solution into the model, tracking the flow of the spray through the structural voids, gaining a better understanding of the spray distribution within paediatric patients.

INSIGHT SURGERY CASE STUDY

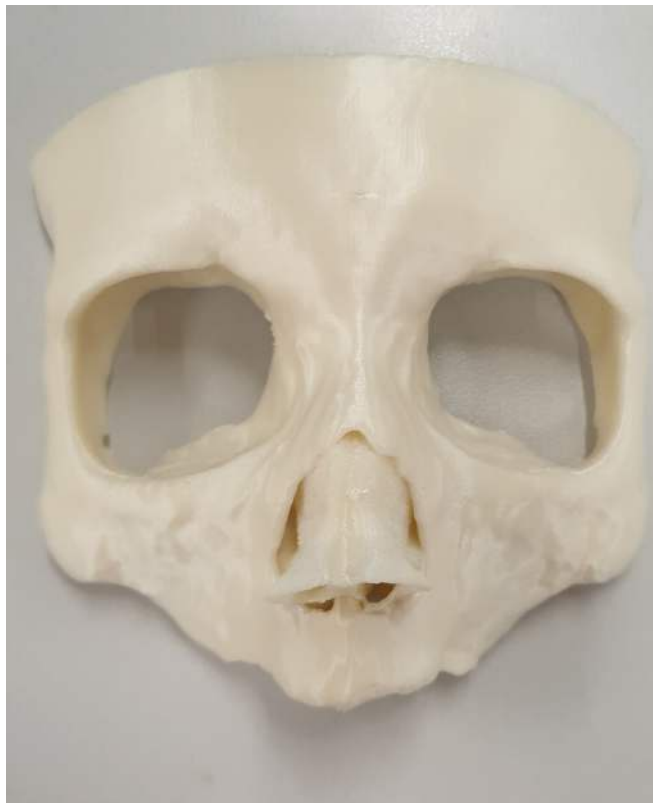

PAEDIATRIC ENT RESEARCH

SPECIALITY: CRANIO-MAXILLOFACIAL

PROCEDURE: RECONSTRUCTION WITH SCAPULA FREE FLAP

DEVICES: 3D PRINTED ANATOMICAL MODEL



OUTCOME / BENEFITS

While 3D printing's core value has been more commonly found in treating complex individual patient cases, hospitals and researchers are increasingly finding the technology useful in broadening their understanding of pathologies and experimenting with treatments.

Traditional techniques can be refined, or entirely new approaches can be devised, using anatomically correct replicas.

CASE SUMMARY

A patient required reconstructive surgery of their left hemimandible. The Cranio-Maxillofacial Surgeon requested assistance in delivering a personalised procedure for a more effective outcome.

DESCRIPTION

Insight Surgery segmented the patient's CT scans and created a virtual model of the patient's skull, mandible and fibula with associated vessels. The surgeon determined the resection from tooth 34 to the sigmoid notch, which meant that a small part of the condyle would be left to anchor the future reconstructive plate, a challenging task given the small size of the bone.

The best cutting plane locations were also found for the fibula, from which the reconstructive flap would be raised. All three guides (two for the resection on the mandible and one to raise the fibula parts) were then 3D printed in Polyamide/PA 12.

The drilling locations for the implant screws were also determined pre-surgery and the reconstructive implant plate itself was 3D printed in titanium.

INSIGHT SURGERY CASE STUDY



CRANIO-MAXILLOFACIAL PRE-SURGICAL PLANNING, SURGICAL GUIDES AND IMPLANT

SPECIALITY: CRANIO-MAXILLOFACIAL

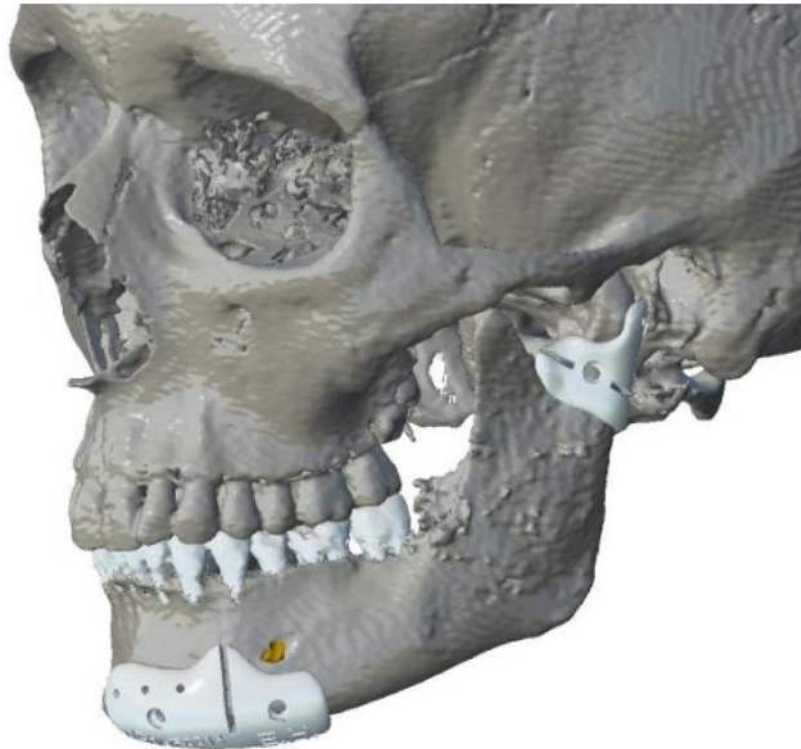PROCEDURE: FIBULA FREE FLAP RECONSTRUCTION

DEVICES: 3D PRINTED PATIENT-SPECIFIC ANATOMICAL MODEL, SURGICAL GUIDES, IMPLANT

OUTCOME / BENEFITS

Using the surgical guides, drilling and placement of the reconstructive plate during live theatre proved to be equally accurate and the plate was implanted securely, the positioning of the screws optimised by the engineer's design.

Surgeons described the surgical guides as easy to use, the procedure was successful, and the patient has made a good recovery.



CASE SUMMARY

A patient required a resection of the right mandible and subsequent reconstruction of the jaw with bone taken from their scapula. The surgeon requested Insight Surgery's assistance in providing personalised treatment for the patient, which would result in a more efficient surgery and more effective outcome. Patient-specific anatomical models, surgical guides and a customised implant were commissioned.

DESCRIPTION

Insight Surgery began by segmenting the patient's CT scan, creating a virtual model of their jaw and cranium, as well as their scapula. Following the surgeon's clinical decisions, such as the location of the resection planes and the positioning of the scapula depending on the location of the future anastomosis, the surgery was digitally simulated. The patient-specific guides and implants were then designed and 3D printed for use in theatre.

Three guides were provided; one for the resection plane on the left angle of the mandible, one for the resection plane on the chin section of the mandible, and one for the scapula to raise the flap. Mirroring techniques of the patient's healthy right mandible and original anatomy were used to gauge the size and shape of the flap taken from the scapula. A titanium reconstruction plate designed to fit the patient's anatomy without the need for in theatre bending was also printed, to secure flap in the remaining part of the mandible.

INSIGHT SURGERY CASE STUDY

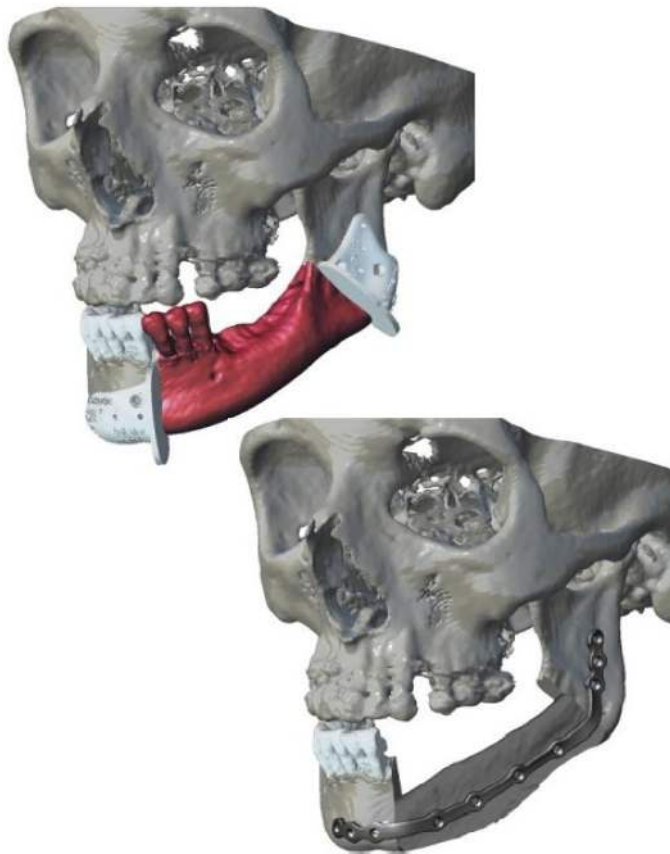


CRANIO-MAXILLOFACIAL PRE-SURGICAL PLANNING, SURGICAL GUIDES AND IMPLANT

SPECIALITY: CRANIO-MAXILLOFACIAL

PROCEDURE: MANDIBULAR RECONSTRUCTION WITH SCAPULA FLAP

DEVICES: 3D PRINTED PATIENT-SPECIFIC ANATOMICAL MODEL, SURGICAL GUIDES AND IMPLANT



OUTCOME / BENEFITS

Using the surgical guides, the team was able to safely and accurately resect the hemimandible and reconstruct the patient's jaw with bone from the shoulder blade. In this case, they were able to recreate the basilar edge of the mandible with the scapula flap.

Additionally, the bespoke plate avoided the traditional need to bend a plate during surgery, saving time in theatre for both the team and the patient. Accurate simulation of the surgery allowed for precise implantation of the plate screws, avoiding interference with teeth roots. The surgery was successful and was carried out without complication.

CASE SUMMARY

In this case, Insight Surgery worked with the surgeon to assist in the design and manufacture of a customised 3D printed titanium plate for a surgical procedure to restore the patient's malar (cheek) symmetry.

Insight Surgery received the CT scans of the patient's head, and using advanced medical segmentation software, reconstructed in 3D the anatomical regions of interest for the upcoming malar surgery. The segmentation process involves the selection of the Hounsfield units corresponding to the appropriate bone areas of interest.

DESCRIPTION

The 3D reconstruction / segmentation of the patient's anatomy from the CT scan was used to virtually plan the surgery in order to aid with the surgeon's pre-surgical planning process.

The implant is designed based on the surgeon's requirements, the virtual simulation of the mirror and the types of screws used in order to accurately match the patient's anatomy. It was then 3D printed in titanium, sterilised by the hospital and then surgically implanted into the patient.

INSIGHT SURGERY CASE STUDY

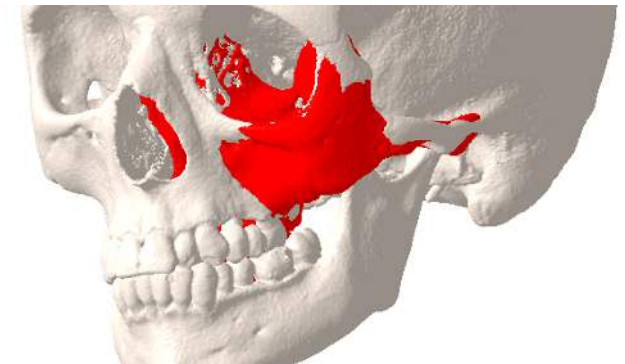
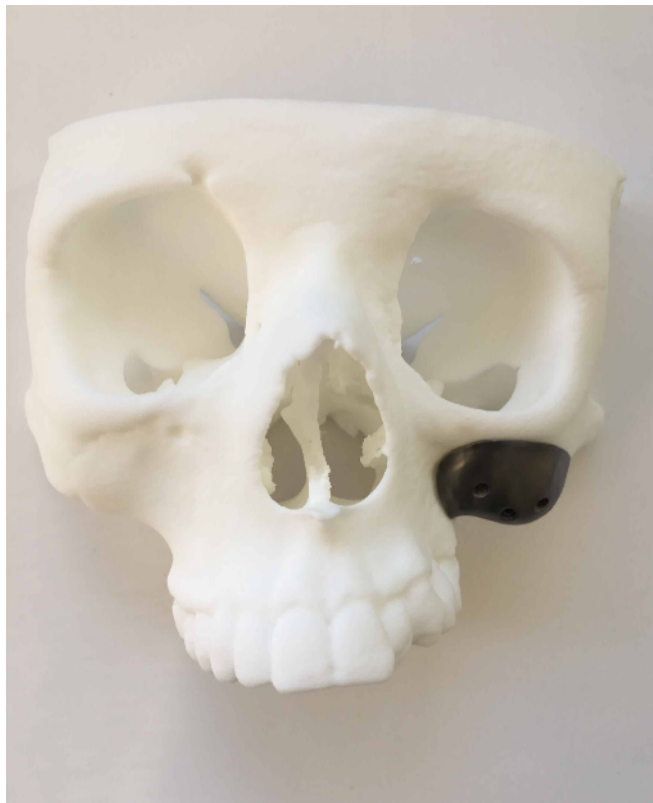

CRANIO-MAXILLOFACIAL VIRTUAL PLANNING & IMPLANT

SPECIALTY: CRANIO-MAXILLOFACIAL

PROCEDURE: MALAR SYMMETRISATION USING PATIENT-SPECIFIC ONLAY IMPLANT

DEVICES: 3D PRINTED PATIENT-SPECIFIC ANATOMICAL MODEL AND IMPLANT



OUTCOME / BENEFITS

It is estimated that using traditional techniques for the creation of malar implants, 10% are removed or replaced because of improper implant size, shape or position. The use of 3D technologies and the virtual planning simulation process enabled a highly accurate implant to be created and implanted that required no further adaptation. The shape of the implant enabled the surgeon to easily position it through a transoral approach.

Post-operatively, the surgeon commented - "It went really well. Fitted perfectly!"

CASE SUMMARY

Following a fall, this patient suffered a huge defect involving the orbital roof and the frontal area. Surgery was needed in order to restore the protective function of the skull and the aesthetic symmetry of the patient.

Taking the patient's CT scan, Insight Surgery's biomedical engineer segmented the data to produce the virtual model of the skull. Virtual surgery was then simulated using software and patient-specific implants were designed and subsequently 3D printed in titanium.

DESCRIPTION

A mirror of the intact anatomy was first created (red) to provide a reference healthy anatomy needed for the restoration. The osteotomy of the superior orbital rim (purple) was simulated virtually, and the mirror used to reposition in order to achieve symmetry.

Two patient-specific implants were then designed with a complementary shape to facilitate positioning. These were then printed in Titanium Alloy for implantation.

INSIGHT SURGERY CASE STUDY

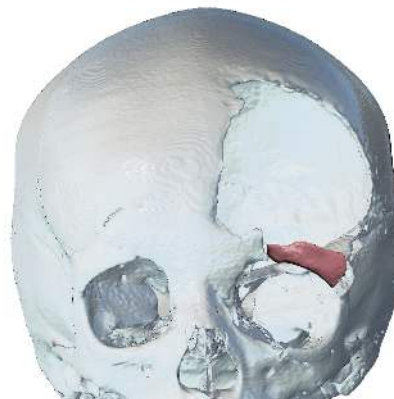



CRANIO-MAXILLOFACIAL VIRTUAL PLANNING & IMPLANT

SPECIALITY: CRANIO-MAXILLOFACIAL

PROCEDURE: CRANIOPLASTY AND ORBITAL ROOF RECONSTRUCTION

DEVICES: 3D PRINTED PATIENT-SPECIFIC IMPLANTS



OUTCOME / BENEFITS

With one implant reconstructing the orbital roof and the other covering the defect in the frontal area, the patient's brain is now protected again, and their aesthetic improved.

CASE SUMMARY

The cleft, oral and maxillofacial team had a paediatric patient that posed unique challenges when they were presented with a rare case of supernumerary teeth, with a tooth growing into the nasal cavity.

This rare condition led the team to consider assistance in planning their surgical approach and therefore requested a 3D printed model of the patient's unique anatomy.

DESCRIPTION

Insight Surgery segmented the patient's CT scan data and printed the model in a bone-like material.

The surgical team utilised the model in their pre-surgical planning and increased their understanding of an incredibly rare pathology. The model will also be used for educational purposes by the department in future.

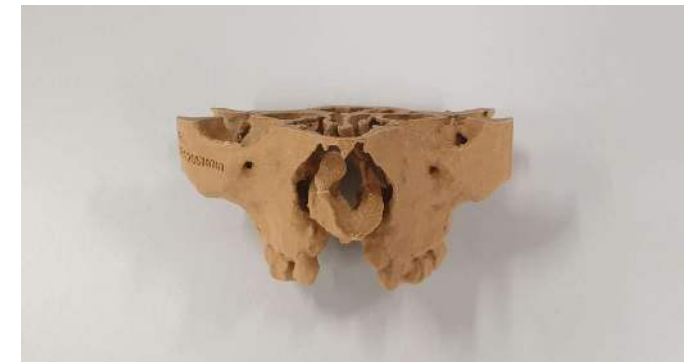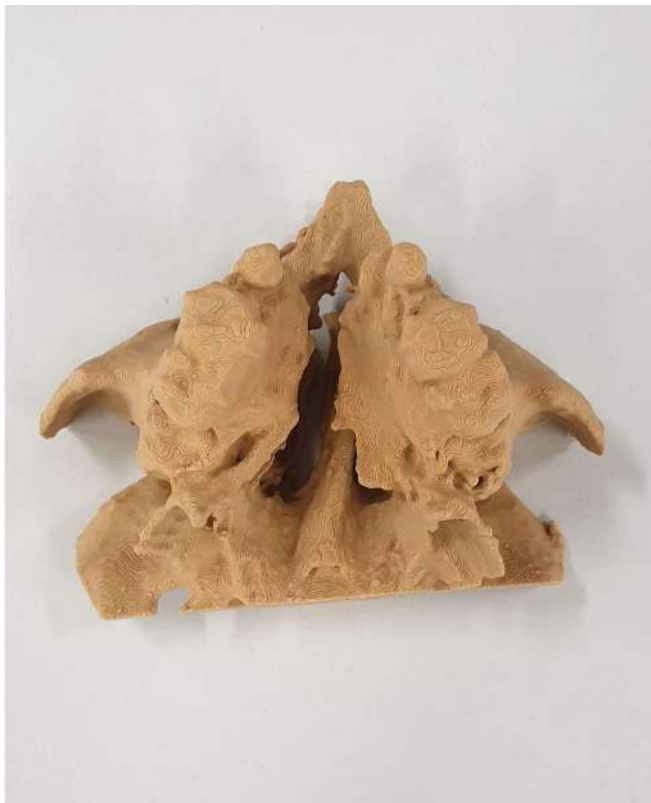INSIGHT SURGERY CASE STUDY

PAEDIATRIC CLEFT/ORAL AND MAXILLOFACIAL PRE-SURGICAL PLANNING

SPECIALITY: CRANIO-MAXILLOFACIAL

PROCEDURE: CLEFT PALATE SURGERY AND SUPERNUMERARY TOOTH REMOVAL

DEVICE: 3D PRINTED PATIENT-SPECIFIC ANATOMICAL MODEL



OUTCOME / BENEFITS

Pre-operative assessment of the patient's condition and planning in three dimensions enabled the surgical removal of the tooth from the nasal cavity, and the cleft palate procedure to be completed with greater speed and accuracy.

The surgery was considered successful and carried out without complication.

CASE SUMMARY

This young female patient had been kicked by a horse, which resulted in several severe fractures within the right orbit, zygoma and maxilla. First, an emergency surgery was performed by the maxillofacial surgeon, who then asked Insight Surgery for assistance ahead of the second surgery.

As the second surgery had to be performed before the bone had any chance to heal (less than a week after the request was made), it wasn't possible to 3D print titanium parts for this patient. For this reason, it was decided that Insight Surgery would perform the virtual simulation of the surgery, and provide a multicoloured 3D printed model.

DESCRIPTION

Insight Surgery first created a virtual model of the patient's skull by segmenting the CT scan of the patient. Particular attention was taken to segment all the scattered pieces of bone separately. Then, using the mirror of the contralateral side which had been kept intact during the trauma, the biomedical engineer repositioned the pieces together on the software, to reconstruct the right side as well as possible.

After a review of the virtual planning with the surgeon, it was decided that a multicoloured 3D printed model would be provided, to enable the surgeon to bend a standard orbital mesh, prior to the surgery. Additionally, the 3D printed model would be used as a reference during the surgery, to help the surgeon with the reconstruction.

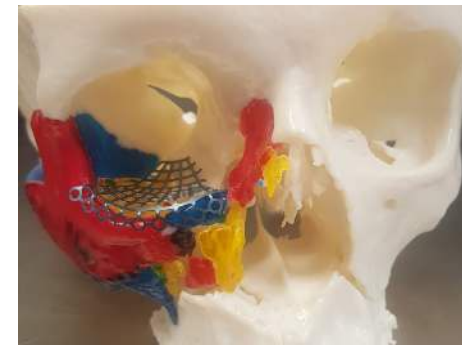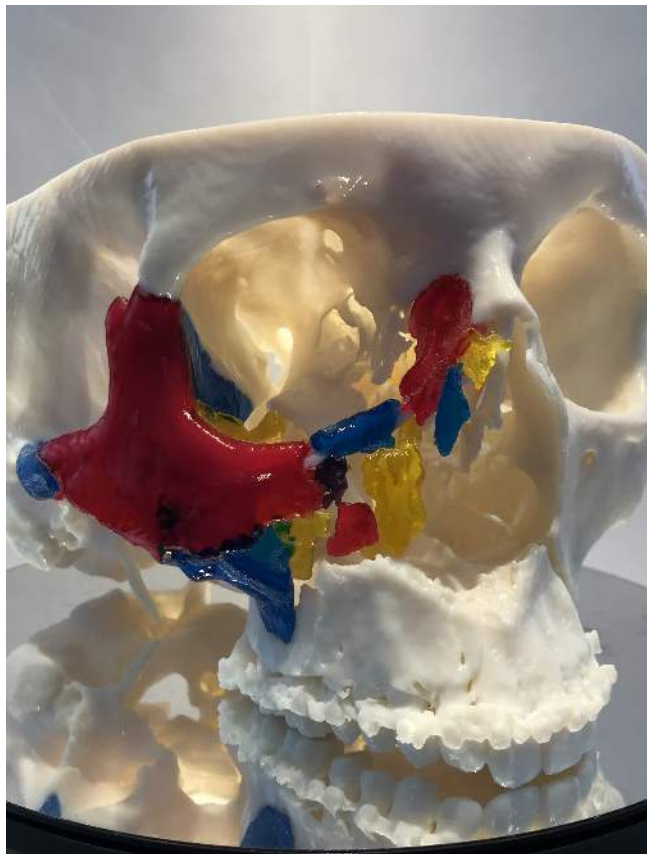INSIGHT SURGERY CASE STUDY

CRANIO-MAXILLOFACIAL PRE-SURGICAL PLANNING, VIRTUAL SIMULATION

SPECIALITY: CRANIO-MAXILLOFACIAL

PROCEDURE: ORBITAL FLOOR AND ZYGOMA RECONSTRUCTION

DEVICE: 3D PRINTED ANATOMICAL MODEL OF THE VIRTUAL SIMULATION



OUTCOME / BENEFITS

The model allowed the surgeon to provide a semi customised solution in this trauma case. It was also very useful during the surgery for the surgeon to locate the scattered bone parts and reposition them as shown on the model.

The surgeon commented *"The operation went very well, I'm quite pleased - good result."* For the patient, this meant less time under anaesthetic, lower risk while in surgery, and an opportunity for a better outcome post-surgery derived from the personalised treatment.

CASE SUMMARY

This patient needed correction of a class 2 malocclusion with vertical maxillary excess.

Ideally, in a smile considered "normal and aesthetic", 2.0mm or less of gingival tissue would be displayed. Clinically, this patient had an excessive gingival display which could be corrected by a 2mm maxillary impaction. The malocclusion would also be corrected at the same time.

The surgeon also noticed that her chin was deviated to the right by around 2mm, and was considering a genioplasty.

DESCRIPTION

Insight Surgery were provided with the Cone Beam CT scan of the patient. The imaging data was first segmented, to create virtual 3D models of the maxillary and mandibular teeth, the infra alveolar nerves, as well as the maxilla and mandible bones.

The digital parts were imported into a specialised software for the virtual simulation of orthognathic surgeries. The osteotomy of the maxilla (Lefort I) and the mandible (BSSO) were simulated. Cephalometric points were placed on the anatomy (on the teeth, bones and soft tissues), to enable accurate tracking of the impact of the simulation.

The 2mm maxillary impaction was performed virtually, and the class I occlusion simulation. At this stage, we noticed that the patient would benefit from a Cant correction, which would also correct the chin asymmetry, without the need for a genioplasty.

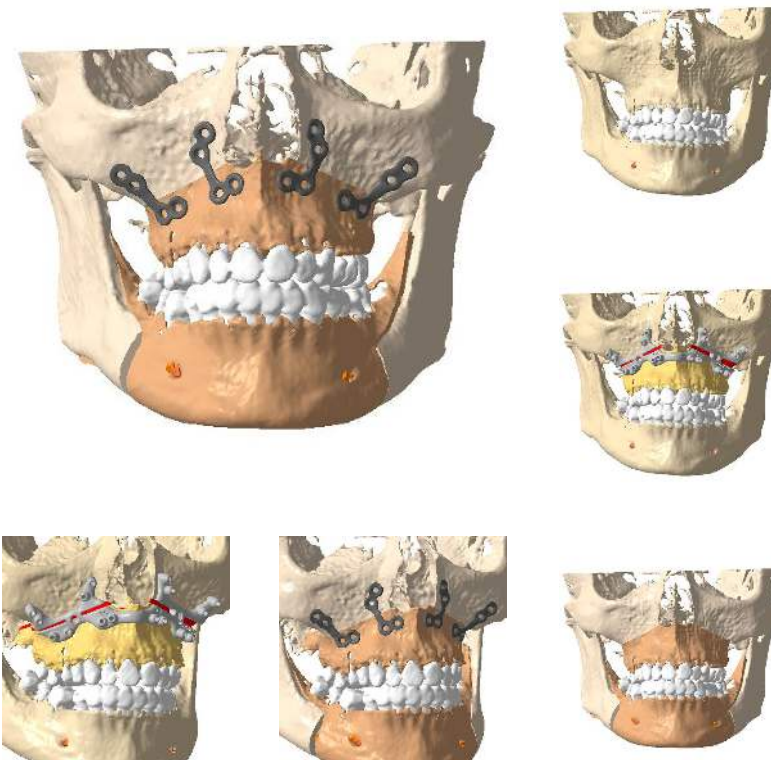
INSIGHT SURGERY CASE STUDY

CRANIO-MAXILLO FACIAL PRE-SURGICAL PLANNING, SURGICAL GUIDE, IMPLANTS

SPECIALITY: CRANIO-MAXILLOFACIAL

PROCEDURE: LEFORT I AND BSSO

DEVICES: 3D PRINTED PATIENT-SPECIFIC SURGICAL GUIDE AND IMPLANTS



OUTCOME / BENEFITS

The virtual simulation was reviewed with the surgeon and approved. In order to facilitate the transfer of the virtual simulation to the theatre, a surgical guide was designed and subsequently 3D printed. Likewise, titanium osteosynthesis plates were designed and 3D printed specifically for this patient.

Performing the surgery virtually beforehand removed the need for a genioplasty. The use of patient-specific devices during the surgery meant a safer procedure (eg the screws are placed away from the teeth roots), less time in the operating room as the clinical decisions are taken outside the theatre and the devices are already shaped exactly for the patient.

CASE SUMMARY

This patient had been allegedly assaulted, suffering complex orbital fractures along with globe injury leading to severe visual deficit and atrophy of the eye. Additionally, the patient suffered from severe social anxiety due to the appearance of the enophthalmos/atrophied globe.

The Oral and Maxillofacial Surgeon was required to perform a complex orbital floor and medial wall reconstruction. Insight Surgery were commissioned to provide two patient-specific devices to support both planning and the actual reconstruction.

DESCRIPTION

Insight Surgery provided a replica of the patient's orbital floor and the patient-specific implant used in the reconstructive surgery.

The orbital model was printed in PA 12 and sterilised for reference use during the operation to help position the 3D printed titanium implant, which had been custom designed for the patient.

INSIGHT SURGERY CASE STUDY



CRANIO-MAXILLOFACIAL PRE-SURGICAL PLANNING AND SURGICAL IMPLANT

SPECIALITY: CRANIO-MAXILLOFACIAL

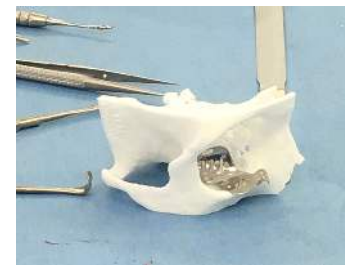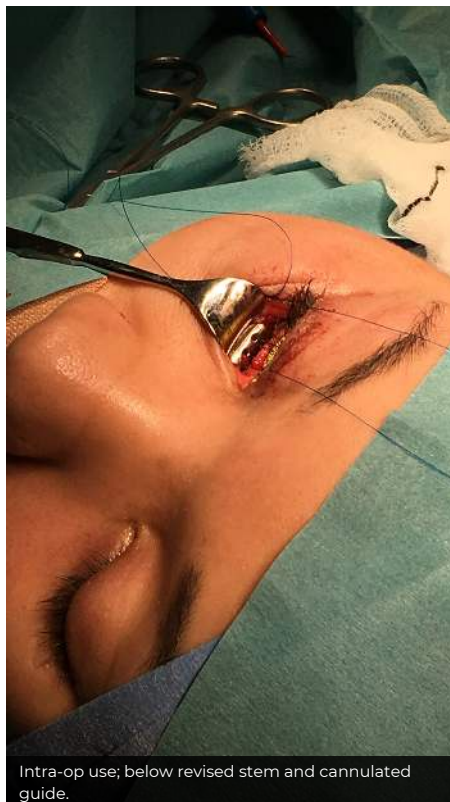PROCEDURE: COMPLEX ORBITAL FLOOR & MEDIAL WALL RECONSTRUCTION

DEVICES: 3D PRINTED PATIENT-SPECIFIC ANATOMICAL MODEL AND IMPLANT

OUTCOME / BENEFITS

The surgeon was able to reconstruct the orbital floor and part of the medial wall to provide a base for the globe.

Furthermore, a buccal fat pad graft was harvested and placed inferior to the globe to restore the volume with excellent preliminary results.



CASE SUMMARY

Faced with a paediatric patient in need of urgent cranio-maxillofacial surgery to reconstruct the mandible bone, the cranio-maxillofacial surgical team sought assistance in understanding the true extent of the surgery required and preplanning the procedure for a better patient outcome. A model of the patient's craniofacial complex with pre-existing metalwork was commissioned.

DESCRIPTION

Insight Surgery segmented the CT scan of the patient's craniofacial complex and printed the model in polywood, a bone-like material, for skeletal tissue, and PLA in an alternative colour, to highlight areas of pre-existing metalwork.

The surgeon used the replica model to understand the complex anatomy, as a reference during surgery, and also as a tool to pre-bend the new plates for the patient which were to be used in surgery.

INSIGHT SURGERY CASE STUDY

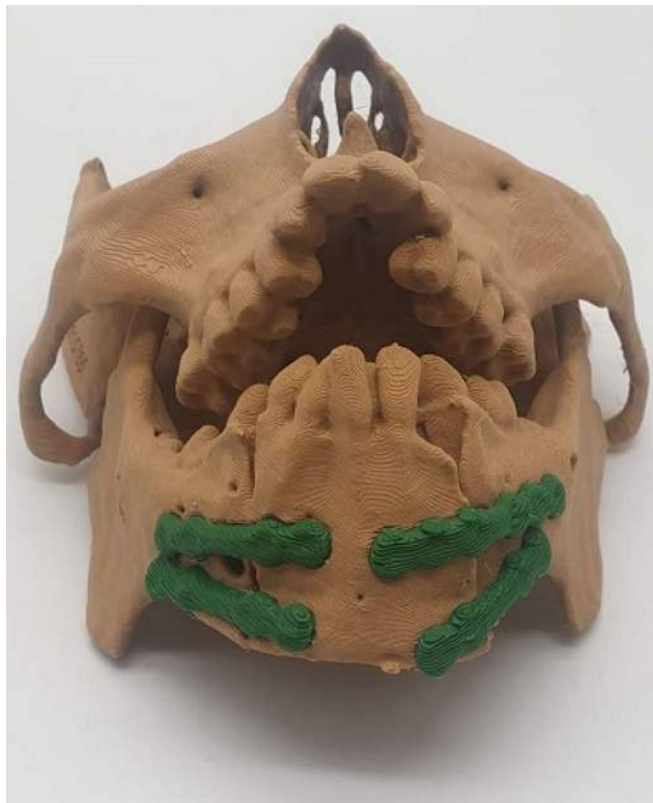

PAEDIATRIC CRANIO-MAXILLOFACIAL PRE-SURGICAL PLANNING

SPECIALITY: CRANIO-MAXILLOFACIAL

PROCEDURE: MANDIBLE RECONSTRUCTION

DEVICE: 3D PRINTED PATIENT-SPECIFIC ANATOMICAL MODEL



OUTCOME / BENEFITS

Understanding the complex anatomy, being able to pre-bend the patient's plates in advance, and having the opportunity to use the model during surgery meant time saved for both the patient and the surgical team in theatre.

CMF SOLUTIONS



WE PRIDE OURSELVES
ON PROVIDING
OUTSTANDING CLIENT
SERVICE, AND ARE
ALWAYS AVAILABLE FOR
A DISCUSSION

EMAIL US
info@insightsurgery.com

CALL US
+1 281 733 2568 (Houston office)
+44 (0) 151 528 8749 (Liverpool
office)
+44 (0) 1865 52 2767 (Oxford
office)
+44 (0) 207 193 5630 (London
office)

FIND US

Texas Medical Center

2450 Holcombe Blvd, Suite X,
Houston, Tx 77021, USA

Alder Hey Children's Hospital

Eaton Road, Liverpool L12 2AP, UK

Nuffield Orthopaedic Centre

Old Road, Oxford OX3 7LD, UK

Wrightington Hospital

Hall Lane, Appley Bridge, Wigan
WN6 9EP, UK

Leeds General Infirmary

Great George Street, Leeds, LS1 3EX,
UK

